

Surgical Options for the Treatment of Obstructive Sleep Apnea

Jon-Erik C. Holty, MD, MS^{a,*}, Christian Guilleminault, MD, DBiol^b

KEYWORDS

• Obstructive sleep apnea • Sleep apnea syndromes • Surgery

Obstructive sleep apnea (OSA) is a highly prevalent condition characterized by increased nocturnal airflow resistance resulting in repetitive episodes of pharyngeal collapse during sleep.¹ Approximately 20% of adults in the United States have OSA (defined as an apnea-hypopnea index (AHI) ≥ 5 /h) with up to 10% having moderate to severe disease (AHI ≥ 15 /h).^{2,3} In addition, between 3% and 10% of children have OSA (AHI ≥ 1 /h).⁴⁻⁷ Obesity, male gender, advancing age, and mandibular-maxillary insufficiency are well-characterized risk factors.⁸ OSA predisposes to increased cardiovascular and cerebrovascular morbidity and mortality, and is associated with excessive daytime sleepiness and neurocognitive underperformance.⁸ Untreated, the 15-year mortality for adults with severe disease is approximately 30% with adjusted mortality hazards ratios of 1.4, 1.7, and 3.8 for mild, moderate, and severe disease, respectively (P -trend = 0.004).²

Conventional nonsurgical OSA therapy necessitates indefinite positive airway pressure (eg, continuous positive airway pressure [CPAP] or bilevel therapy) that works by pneumatically stenting open the upper airway, thus preventing apneas and hypopneas during sleep.⁹⁻¹¹ CPAP is an effective treatment modality for OSA, improving symptoms (eg, excessive daytime sleepiness, quality of life) and reducing cardiovascular mortality.^{12,13} Unfortunately, more than 50% of patients with OSA are intolerant of and ultimately reject CPAP therapy.^{14,15} Common complaints include mask discomfort and leak, rhinorrhea, conjunctivitis, dry mouth, nasal congestion, aerophagia, claustrophobia, and chest wall discomfort.⁶ Individuals intolerant of CPAP therapy have a 10% absolute increased mortality risk (compared with adherent subjects) at 5 years.^{16,17}

Contract/Grant Support: None.

Conflict of interest: None.

^a Division of Pulmonary, Critical Care and Sleep Medicine, Department of Medicine, VA Palo Alto Health Care System, 3801 Miranda Avenue, Palo Alto, CA 94304, USA

^b Division of Sleep Medicine, Stanford University School of Medicine, Stanford Medical Outpatient Center, 450 Broadway Street, Pavillon C, Redwood City, CA 94063-5074, USA

* Corresponding author.

E-mail address: jholty@stanford.edu

Med Clin N Am 94 (2010) 479–515

doi:10.1016/j.mcna.2010.02.001

0025-7125/10/\$ – see front matter. Published by Elsevier Inc.

medical.theclinics.com

Effective surgical therapies for OSA predate the first reported use of CPAP by Sullivan and colleagues⁹ in 1981 and Rapoport and colleagues¹⁸ in 1982. Tracheostomy was employed as early as 1969¹⁹ and Kuo and colleagues²⁰ in 1979 (and later Bear and Priest²¹ in 1980) reported the results of mandibular advancement for the treatment of OSA. In 1952, Ikematsu²² began removing excessive oropharyngeal tissue to alleviate snoring and reported the results of his palatopharyngoplasty with partial uvullectomy in 152 habitual snorers in 1962. In the late 1970s, Fujita and colleagues²³ adapted Ikematsu's procedure and introduced the uvulopalatopharyngoplasty as a new surgical approach to treat OSA.²⁴ Because the anatomic cause of OSA is heterogeneous with most OSA patients having multiple concurrent pharyngeal abnormalities,^{25–27} surgical procedures have evolved to address specific anatomic airflow limitations and to augment the effectiveness of existing procedures. This review describes the pathophysiology of OSA, the rationale for surgery, and the various surgical techniques used to treat OSA.

PATHOPHYSIOLOGY OF OSA

Patients with OSA have nocturnal airflow restriction resulting from upper-airway collapse between the naso- and hypopharynx.²⁸ During normal breathing, contraction of the diaphragm results in an increased thoracic volume that generates negative intrapleural pressure drawing air down to the alveoli. During a normal negative pressure inspiration, upper-airway reflexes phasically activate pharyngeal muscles (eg, genioglossus, tensor palatini, geniohyoid, stylohyoid) to dilate and stiffen the upper airway to maintain patency.^{29–32} Pharyngeal dilator muscle activity is reduced in normal and OSA individuals during sleep.^{30,33} However, patients with OSA have anatomically smaller upper airways and diminished pharyngeal dilator tone resulting in clinically significant airflow limitation (eg, apneas and hypopneas) during nocturnal negative pressure inspiration.^{28,34,35} Most individuals with OSA have multiple pharyngeal abnormalities²⁵ with anatomic airway narrowing primarily in the lateral dimension.^{36,37}

In addition, patients with OSA are often obligatory mouth breathers during sleep.³⁸ Nasal breathing (compared with mouth breathing) is more efficient because the nasal cavity has a more constant resistance (compared with the oral cavity) and because stimulation of nasal receptors is involved in activating the pharyngeal dilators.³⁹ In normal individuals, a transition from nasal to oral breathing results in a greater risk of pharyngeal collapse because of greater negative inspiratory pressures needed to overcome increased airway resistance.³⁹ Experimental nasal obstruction^{40–42} or inhibiting the nasopharyngeal reflex (by applying topical anesthesia)⁴³ causes nocturnal apneas, hypopneas, and oxygen desaturation in normal individuals.

OSA is in part a neurologic disorder of the upper airway.^{30,33,44,45} Pharyngeal collapse is often caused by abnormal activation of pharyngeal dilator muscles from dysfunctional pharyngeal reflexes.⁴⁶ In patients with nocturnal upper-airway resistance, repetitive vibratory trauma (eg, snoring) and tremendous swings in pharyngeal pressures (caused by apneas and hypopneas) during sleep results in pathologic injury to the pharyngeal dilator muscles and nerves.^{33,47,48} This irreversible damage predisposes the upper airway to inspiratory collapse during sleep.^{45,49–51}

RATIONAL FOR OSA SURGERY

The aim of OSA surgery is to eliminate airway collapse and reduce airway resistance during sleep without causing impairment to the normal functions of the upper airway and associated structures. Indications for surgery depend on: (1) the severity of OSA

and comorbid medical conditions; (2) the severity of symptoms (eg, excessive daytime sleepiness); and (3) the anatomic location(s) causing obstruction. General indications for surgery include moderate-severe OSA, severe excessive daytime sleepiness (even when the AHI is $\leq 20/h$), OSA with comorbid conditions (eg, arrhythmias, hypertension), OSA with anatomic airway abnormalities, and failure of medical OSA management.⁵² Upper-airway abnormalities amenable to surgery include those within the nasal cavity (eg, deviated septum, polyps, hypertrophic turbinates, collapsible nasal valves), nasopharynx (eg, stenosis, adenoids), oropharynx (eg, palatine tonsils, elongated uvula, redundant mucosal folds, low hanging palate, webbing), and hypopharynx (eg, lingual tonsils, large tongue base, redundant aryepiglottic folds) (Table 1). Relative contraindications to surgery include morbid obesity (except for bariatric surgery and tracheostomy), severe or unstable cardiopulmonary disease, active alcohol/illicit drug abuse, older age, unstable psychological problems, or unrealistic expectations from surgical therapy.

All adult OSA patients should be offered a nonsurgical treatment option (eg, CPAP) before proceeding to surgery. Even in patients electing to proceed directly to surgery, a trial of CPAP therapy may be helpful as this is a noninvasive means to determine the expected extent of symptom abatement after surgery. Preoperative CPAP is indicated in patients with severe OSA (AHI $>40/h$ with severe nocturnal oxygen desaturation $<80\%$) and should be continued postoperatively until 2 weeks before the postoperative polysomnogram.⁵³

In children, early recognition of OSA and prompt correction of anatomic upper-airway abnormalities is paramount. By the age of 4 years, 60% of the adult craniofacial skeleton is attained, with 90% by age 12 years.^{54–56} Children with pharyngeal obstruction (eg, tonsillar hypertrophy, turbinate enlargement) protect the patency of the airway by sleeping in the prone or side position with an extended, flexed head, and an anteriorly displaced tongue.⁵⁷ Anterior displacement of the tongue is associated with narrower upper and shorter lower dental arches,^{57–61} posterior displacement of the mandible,^{60,62} with resultant development of mandibular retrusion, increased overjet, and facial height^{63–68} (all known risk factors for OSA).^{58,69} Thus, early recognition

Table 1 Anatomic location of pharyngeal obstruction in relationship to surgical procedure		
Anatomic Treatment Effect	Anatomic Obstruction	Surgical Procedure
1. Bypass upper airway	Collapsed airway	Tracheostomy
2. Soft tissue removal	Nasal cavity	Polypectomy, radiofrequency ablation of the turbinates
	Nasopharynx	Adenoidectomy
	Oropharynx	Tonsillectomy
		Uvulopalatopharyngoplasty
		Laser-assisted uvulopalatoplasty
3. Skeletal/soft tissue modification	Hypopharynx	Midline glossectomy
		Tongue base reduction
	Nasal cavity	Septoplasty
	Oropharynx	Rapid maxillary expansion
	Hypopharynx	Mandibular advancement
		Genioglossal advancement
		Hyoid myotomy suspension
	Oro- and hypopharynx	Maxillomandibular advancement

and surgical correction of significant airway obstruction in children is necessary to prevent abnormal craniofacial development and the irreversible damage to the pharyngeal dilator reflexes that potentially can lead to the lifelong consequences of OSA.

In adults and children, preoperative upper airway assessment is necessary to determine the level of obstruction (anywhere between the nose and epiglottis) and plan the optimal surgical approach. Preoperative fiberoptic endoscopy (performed with a Müller maneuver) and cephalometric analysis are helpful to classify the type of airway obstruction and identify obstructions of the hypopharynx.^{26,70} Computed tomography may have added benefit.⁷¹ The anatomy of the upper airway is classified into 3 general obstructive types (Fujita classification): (1) type 1: narrow oropharynx (eg, large tonsils, enlarged uvula, pillar webbing) with normal palatal arch position; (2) type 2: low arched palate with relatively large tongue; further subdivide into 2a (predominantly oropharyngeal abnormality) and 2b (abnormality involves oro- and hypopharynx); (3) type 3: hypopharyngeal obstruction (eg, retrognathia, floppy epiglottis, enlarged lingual tonsils) with normal oropharynx.^{72,73} The type of obstruction is often modified whether nasal obstruction concurrently exists. Surgical procedures address specific upper-airway abnormalities (eg, uvulopalatopharyngoplasty for type 1, genioglossus advancement for type 3, maxillomandibular advancement for combined type 1, 2 and 3). Preoperative pharyngeal anatomy, OSA severity, and patient preference (eg, recovery time, prolonged facial paresthesias, and malocclusion) are all contributing factors influencing the surgical decision.

SURGICAL SUCCESS

Various surgical procedures are now available to increase the posterior airspace and treat OSA in CPAP intolerant patients. However, no surgical treatment is 100% effective. Similar to previous reviews of OSA surgery,^{74,75} we defined surgical success as an AHI less than 20 and a reduction in AHI of 50% or more after surgery.⁷⁶ Where possible, we provide surgical cure rates (defined as an AHI <5/h in adults and <1/h in children).⁷⁷

PHARYNGEAL SURGICAL PROCEDURES

Individual surgical procedures are described in the following sections for the treatment of OSA organized by the treatment effect on the anatomic airway obstruction (eg, bypassing the upper airway obstruction, removal of soft tissue structures, or skeletal (or soft tissue) modification) (see [Table 1](#)).

Procedures that Bypass the Upper Airway Obstruction

Tracheostomy

In 1965, Valero and Alroy⁷⁸ reported improvement in nocturnal oxygenation in a patient with progressive respiratory failure secondary to traumatic micrognathia. Kuhlo and colleagues in 1969¹⁹ followed by Lugaresi and colleagues in 1970^{79,80} were the first to effectively treat OSA (or Pickwickian syndrome) by means of a tracheostomy. By bypassing the upper airway, tracheostomy is purported to be curative for OSA.⁸¹ Although many studies purport resolution of airway obstruction after tracheostomy,^{82–85} relatively few studies report pre- and posttracheostomy polysomnography parameters (eg, AHI) ([Table 2](#)).^{81,86–91}

The largest case series ($n = 50$) reported complete resolution of obstructive apneas after tracheostomy.⁸¹ Of 9 studies evaluating 61 patients, tracheostomy was highly effective at eliminating obstructive apneas (apnea index went from

Table 2 Efficacy of tracheostomy for OSA ^a												
Demographics				Apnea Index ^b			AHI (REM) ^c			Apnea-Hypopnea Index (NREM) ^c		
Study	N	Age (y)	Follow-up (mo)	Pre-Trach	Post-Trach	P-value ^d	Pre-Trach	Post-Trach	P-value ^d	Pre-Trach	Post-Trach	P-value ^d
Haapaniemi et al, 2001 ⁸⁶	7	53.4 ± 9.8	60.9 ± 30.7	–	–		–	–		–	–	
Kim et al, 1998 ⁸⁷	23	47.0 ± 12.4	–	–	–		58.5 ± 34.1	26.0 ± 31.2		92.5 ± 39.1	19.8 ± 26.3	
Fletcher, 1989 ⁹⁵	1	–	51.0	114.0	0.0		–	–		–	–	
Fletcher et al, 1987 ⁸⁸	8	55.4 ± 6.8	9.0 ± 3.2	84.6 ± 38.7	0.0 ± 0.0		–	–		–	–	
Guilleminault et al, 1981 ⁸¹	4	–	30.0 ± 6.9	94.5 ± 19.8	0.4 ± 0.5		–	–		–	–	
Sugita et al, 1980 ⁹⁰	1	40.0	3.0	77.0	0.0		–	–		–	–	
Weitzman et al, 1980 ⁹⁶	10	47.5 ± 2.4	0.3 ± 0.4	96.1 ± 21.9	1.1 ± 3.3		79.0 ± 18.6	26.5 ± 25.2		113.7 ± 23.0	25.8 ± 25.4	
Motta et al, 1978 ¹⁰¹	6	47.0 ± 4.0	7.5 ± 6.3	73.0 ± 12.2	0.0 ± 0.0		–	–		–	–	
Weitzman et al, 1978 ¹⁰⁰	1	67.0	0.5	96.7	4.1		–	–		–	–	
Summary	61	49.3 ± 9.9	19.0 ± 26.3	88.4 ± 25.7	0.5 ± 1.9	<0.001	63.8 ± 31.9	26.2 ± 29.2	<0.001	98.9 ± 36.0	21.6 ± 25.8	<0.001

Abbreviations: N, number; NREM, nonrapid eye movement sleep; REM, rapid eye movement sleep; Trach, tracheostomy.

^a Mean (or percent) ± standard deviation. – denotes not reported.

^b The apnea index is the average number of obstructive apneas per hour during sleep.

^c The AHI is the average number of obstructive apneas and hypopneas per hour during sleep.

^d P-value calculated via an extended t-test and evaluates pre- and posttracheostomy measures.

88/h before to 0.5/h after tracheostomy; $P < .001$) (see **Table 2**). However, patients may have persistent hypopneas with a surgical success rate of approximately 73% (see **Tables 2** and **3**). Rodman and Martin⁹² reported persistent (although generally improved) obstructive apneas and oxygen desaturations in 3 morbidly obese patients after tracheostomy caused by kinking of the tracheostomy tube during sleep or external obstruction by the patient's own soft tissues. Haapaniemi and colleagues⁸⁶ reported that although obstructive apneas improved after tracheostomy (mean follow-up 5.1 years), most patients had persistent oxygen desaturations with many having oxygen dip indexes ($\geq 4\%$) of $\geq 15/h$. Fletcher and Brown⁹³ reported persistent REM-associated desaturations after tracheostomy in patients with OSA with concomitant chronic obstructive pulmonary disease. Despite improvements in obstructive apneas after tracheostomy, emergence or worsening of central apneas is frequently observed, although generally resolves within 3 to 6 months.^{80,81,89,94–98}

Tracheostomy is effective at preventing OSA-related arrhythmias,^{98–100} reducing pulmonary artery pressures,^{80,81,101} and improving hypertension^{81,88,100–103} and diabetes¹⁰² in patients with OSA. Many (but not all)⁸⁶ studies have reported near complete resolution of nocturnal symptoms and daytime sleepiness.^{80,81,84,90,91,96,100,101,103–106} A retrospective analysis by He and colleagues¹⁰⁷ suggested a mortality benefit of tracheostomy (0% vs 38% mortality at 8 years) compared with no OSA therapy. Partinen and colleagues^{108,109} found similar mortality benefits (0% vs 11% at 5 years) after tracheostomy.

Unfortunately, tracheostomy has several problems including patient dissatisfaction (eg, psychosocial aspects), perioperative complications (eg, wound infection, tissue necrosis, bleeding), recurrent bronchitis, granulation tissue, trachea-innominate fistula formation, and stoma stenosis (often requiring surgical revision).^{105,110–115} Perioperative mortality is higher in obese individuals than in nonobese individuals.¹¹⁶ Permanent tracheostomy (either tube¹¹¹ or tube-free¹¹⁷) is currently used in highly select cases with severe OSA who are intolerant of CPAP (and poor candidates for other surgical procedures). A temporary tracheostomy is occasionally used before other OSA procedures (eg, uvulopalatopharyngoplasty, bariatric surgery) to protect the airway, particularly in morbidly obese subjects.¹¹⁸

Closure of a permanent tracheostomy (after resolution of OSA by other surgeries or weight loss¹¹⁹) may be associated with a relatively high complication rate ($\sim 30\%$), especially when done with a 3-layer as opposed to a de-epithelialization technique.^{120,121} In addition, long-term tracheostomy may cause pharyngeal tissue obstruction (eg, granulation tissue, tracheomalacia) that may predispose to OSA after closure.^{122,123}

Procedures that Remove Soft Tissue

Laser-assisted uvulopalatoplasty (LAUP)

This office-based procedure (similar to uvulopalatopharyngoplasty, but omitting tonsillectomy) uses a CO₂ laser to shape the soft palate and is an effective surgical technique for snoring ($\sim 90\%$ success), but has limited OSA efficacy (see **Table 3**).¹²⁴ Two randomized trials of LAUP found no significant change in the AHI after surgery compared with those randomized to no surgery.^{125,126} A meta-analysis of these 2 studies found no statistically significant difference in daytime sleepiness (measured by the Epworth sleepiness scale) between surgery and control groups (mean difference -1.4 ; 95% confidence interval [CI] -5.0 – 2.2).¹²⁷ More worrisome is that LAUP may worsen OSA in up to 21% of patients.¹²⁸ LAUP is not approved by the American Academy of Sleep Medicine to treat OSA.¹²⁹ In addition, complications are common

Table 3
Comparison of surgical efficacy for OSA^a

Demographics				AHI ^b			Cure (%) ^c	Success (%) ^c	Ref.
Study	N	Studies	Age (y)	Before Surgery	After Surgery	% Change			
Bariatric surgery ^f	437	16	38.8 ± 14.9	53.3 ± 38.2	15.3 ± 18.7	−72.6 ± 60.6	44	–	338,339
GA	91	4	–	53.9	17.3	−67.8	–	62	134
HS	101	4	–	38.7	25.0	−33.0	–	50	134
HS and GA (or mortised genioplasty)	328	7	–	33.5	15.2	−58.0	–	55	134
LAUP	72	3	–	–	–	–	7	49	77
MMA	627	22	44.4 ± 9.4	63.9 ± 26.7	9.5 ± 10.7	−85.0 ± 18.2	43	86	266
Midline glossectomy	74	5	–	53.0	24.2	−54.4	–	50	134
Radiofrequency ablation (tongue)	394	11	–	37.0	23.4	−35.7	–	36	134
RME									
Children	88	3	7.1 ± 0.7	10.9 ± 4.7	0.8 ± 1.3	−91.0 ± 20.2	–	–	320
Adults ^d	10	1	27.0 ± 0.6	19.0 ± 1.3	7.0 ± 1.3	−63.2 ± 7.1	70	90	321
Tonsillectomy	1,079	23	6.5	18.6	4.9	−73.7	60	–	177,178
Tongue base suspension	77	6	–	29.0	16.3	−32.9	–	35	134
Tracheostomy ^e	33	2	47.2 ± 10.4	98.9 ± 36.0	26.2 ± 29.2	−79.2 ± 25.8	–	73	87,96
UPPP	992	37	48.1	60.0	–	−38.2	16	52	75,77
Multimodality surgery ^g	1,978	58	46.2	48.0	–	−60.3	–	66	74

Abbreviations: BMI, body mass index; GA, genioglossus advancement; HS, hyoid suspension; LAUP, laser-assisted uvulopalatoplasty; MMA, maxillomandibular advancement; N, number; RME, rapid maxillary expansion; UPPP, uvulopalatopharyngoplasty.

^a Plus-minus values are mean (or percent) ± standard deviation. – denotes not reported.

^b The AHI is the average number of apneas and hypopneas per hour during sleep.

^c Surgical success defined as the percent of subjects with an AHI <20/h and a ≥ 50% reduction in the AHI after surgery. Surgical cure defined as an AHI <5/h after surgery. For tonsillectomy, surgical cure was defined as an AHI <1/h after surgery.

^d Surgically assisted RME involved horizontal osteotomies.

^e The AHI for tracheostomy reported during non-REM sleep only and included only obstructive apneas and hypopneas.

^f A statistically significant reduction in BMI was noted at 18 months after bariatric surgery (pre-BMI 53.9 ± 15.7 vs post-BMI 37.8 ± 14.8 kg/m²; *P* < .001).

^g Multimodality surgery refers to simultaneous nasal, palate, and/or base of tongue surgery for OSA.

including early postoperative pharyngeal edema,^{130,131} with up to 59% complaining of persistent side effects (27% difficulty swallowing; 27% globus sensation in throat) after LAUP.¹²⁷

Midline glossectomy

Surgical removal of the center portion of the tongue base (usually via laser) was proposed by Fujita and colleagues¹³² and Woodson and Fujita¹³³ in 1991 for the treatment of OSA in patients with hyopharyngeal obstruction. A review of 5 case series (n = 74) showed a surgical success rate of approximately 50% (see **Table 3**).¹³⁴ Postoperative bleeding and pharyngeal edema requiring protective tracheostomy is not uncommon after surgery.^{132,133}

Radiofrequency ablation of the tongue

Radiofrequency ablation uses a probe to precisely direct temperature-controlled radiofrequency energy to heat (between 60 and 90°C) and ablate target tissues without causing collateral damage to adjoining structures.¹³⁵ Radiofrequency treatment of the tongue base does not require general anesthesia, but usually requires multiple treatment sessions over several weeks, and is successful at eliminating snoring.^{135–137} Eleven case series describing 394 patients with OSA (mean AHI 37/h) undergoing radiofrequency ablation of the tongue reported a surgical success rate of only 36% (see **Table 3**).¹³⁴ Statistically significant improvements in subjective daytime sleepiness and health-related quality of life were observed in most, but not all studies.^{135,138–145} Radiofrequency ablation of the tongue is generally considered adjunctive (not primary) OSA treatment in select patients.¹³⁴

Radiofrequency ablation of the turbinates (and other nasal procedures)

A relationship between nasal obstruction, mouth breathing and symptoms of OSA was first described in the 1800s.^{146–150} Increased nasal resistance may result from septal deviation, turbinate hypertrophy, chronic nasal congestion, polyps, or collapsible valves. Various procedures include polypectomy, radiofrequency ablation of the turbinates, alar valve or rim reconstruction, and septoplasty (eg, straightening of the septum). Nasal surgery is generally not curative,^{151,152} but can improve the AHI, and is often used in a multimodality surgical approach or to decrease CPAP pressure requirements.^{153–155} In addition, surgical correction of nasal obstruction improves health-related quality of life in patients with OSA.¹⁵⁶

Inferior turbinate enlargement is a frequent cause of nasal obstruction. Radiofrequency ablation is a highly successful surgical procedure producing volumetric inferior turbinate reduction. Radiofrequency ablation heats the hypertrophied turbinates causing scar tissue with resulting shrinkage over 1 to 3 weeks.¹⁵⁷ This procedure is generally performed in the outpatient setting with minimal discomfort beyond nasal stuffiness lasting 3 to 5 days.¹⁵⁸

Radiofrequency volumetric soft palate tissue reduction (somnoplasty)

Somnoplasty involves directed radiofrequency energy to ablate and reduce soft tissues of the palate.^{157,159–161} Decreased snoring occurs via scar-induced stabilization of the soft palate. Although symptom (eg, snoring) improvement after surgery is reported,^{136,162} evidence for improvement of OSA is lacking.^{163–165} A recent randomized placebo-controlled trial in patients with mild OSA found no statistically significant improvement in the AHI or symptoms after somnoplasty.¹⁶⁶

Tonsillectomy

Tonsillectomy is one of the most common surgical procedures in children.^{167,168} OSA is a frequent indication for tonsillectomy and is considered first-line therapy for

children with OSA.^{167,169} Surgical tonsillectomy techniques vary, but generally complete resection of the tonsils with adenoidectomy (if necessary) is preferred (**Fig. 1**).¹⁷⁰ Partial intracapsular tonsillectomy (eg, tonsillotomy) has been found to reduce postoperative morbidity (eg, pain),^{171–175} but postoperative objective measures of efficacy (eg, AHI reduction) are lacking.¹⁷⁶

Tonsillectomy is curative (AHI <1/h) in 60% of pediatric cases of OSA (see **Table 3**).^{177,178} Higher presurgery AHI and body mass index (BMI, calculated as weight in kilograms divided by the square of height in meters) are risk factors for residual disease after tonsillectomy.^{179,180} In complicated cases of pediatric OSA (eg, morbid obesity, severe OSA), tonsillectomy is curative in 39% of children compared with 74% in uncomplicated cases.¹⁷⁸ Children with residual OSA after tonsillectomy may benefit from rapid maxillary expansion.¹⁸¹ Tonsillectomy improves quality of life parameters (short- and long-term) in children with OSA,^{182,183} with improvements in behavior scores¹⁸⁴ and sleep disturbances.^{185,186}

Self-limited pain and swelling of the throat is common after tonsillectomy. Risks for postoperative complications include younger age (<24 months), increased severity of OSA, craniofacial abnormalities, obesity, poor functional status (eg, hypotonia, failure to thrive) and cor pulmonale.^{182,187} Life-threatening complications are rare,¹⁸⁸ but postoperative respiratory failure requiring mechanical ventilation (usually transiently during postsurgery recovery) occurs in approximately 30% of children.^{187,189} However, children left intubated electively after tonsillectomy have higher complication rates.¹⁹⁰ Hemorrhage, dehydration, and pulmonary edema occur in approximately 9% of cases.¹⁹¹

Uvulopalatopharyngoplasty

Fujita and colleagues²³ and Conway and colleagues²⁴ adapted Ikematsu's surgical snoring procedure²² and reported his uvulopalatopharyngoplasty (UPPP) results for treating OSA in 1980. This operation enlarges the oropharyngeal airway lumen by

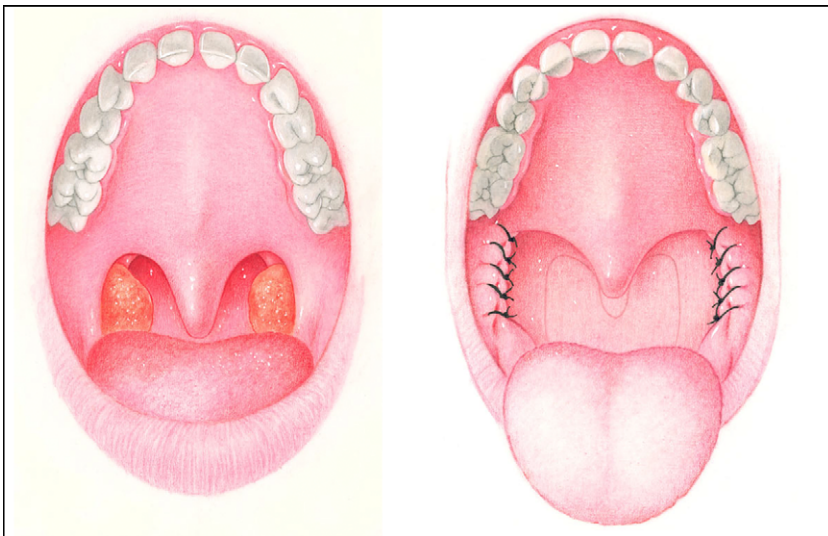


Fig. 1. Tonsillectomy. The primary treatment of OSA in children with tonsillar enlargement is tonsillectomy usually with concurrent adenoidectomy. To prevent collapse and improve OSA success, it is preferable that the lateral pharyngeal walls are sutured.

excising redundant tissues from the soft palate, tonsillar pillars, and uvula (**Fig. 2**). UPPP is currently the most widely performed OSA pharyngeal surgical technique in adults.⁷⁷ Several variations of the UPPP have been proposed including the methods of Fujita and colleagues,^{23,192,193} Simmons and colleagues,¹⁹⁴ Fairbanks,¹⁹⁵ Dickson and Blokmanis,¹⁹⁶ Friedman and colleagues,¹⁹⁷ and Powell and colleagues¹⁹⁸ (uvulopalatal flap surgery). Uvulopalatal flap surgery (**Fig. 3**) reduces the risk of nasopharyngeal incompetence and is associated with less postoperative pain, but is contraindicated in patients with excessively long or bulky soft palates (or uvulas).^{199–201} Woodson and Toohill²⁰² developed transpalatal advancement pharyngoplasty, which combines a UPPP with removal of the posterior hard palate (via a curvilinear palatal incision), with subsequent advancement of the mucoperiosteal flap and suturing to the alveolar mucoperiosteum (**Fig. 4**). This technique is associated with a decrease in retropalatal collapsibility and an increase in the retropalatal airspace compared with traditional UPPP, and may provide higher surgical success and cure rates.^{201,203}

There are no known randomized controlled trials of UPPP that assess pre- and post-surgery AHI,^{74,204,205} and many studies do not report objective postsurgery sleep data.²⁰⁶ One randomized trial found no statistically significant difference in the oxygen desaturation index between the surgery and conservative management groups.^{204,207} UPPP is highly effective for eliminating snoring, with success rates between 70% and 90%.¹⁹³ However, several meta-analysis have reported surgical success rates for OSA between 40% and 60%, and a surgical cure rate (an AHI <5/h) of only 16%

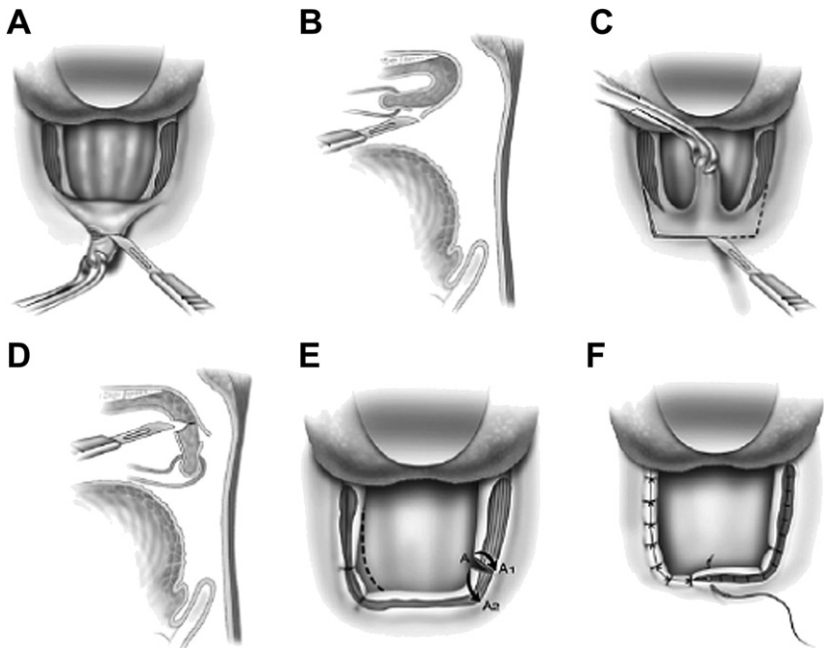


Fig. 2. Uvulopalatopharyngoplasty. This operation enlarges the oropharyngeal airway lumen by excising redundant tissues from the soft palate, tonsillar pillars, and uvula. Shown is Friedman's submucosal uvulopalatopharyngoplasty technique (A–F). (Reproduced from Friedman M, Schach M, Schach P. Surgery of the palate and oropharynx. *Otolaryngol Clin N Am* 2007;40:835; with permission from Elsevier.)

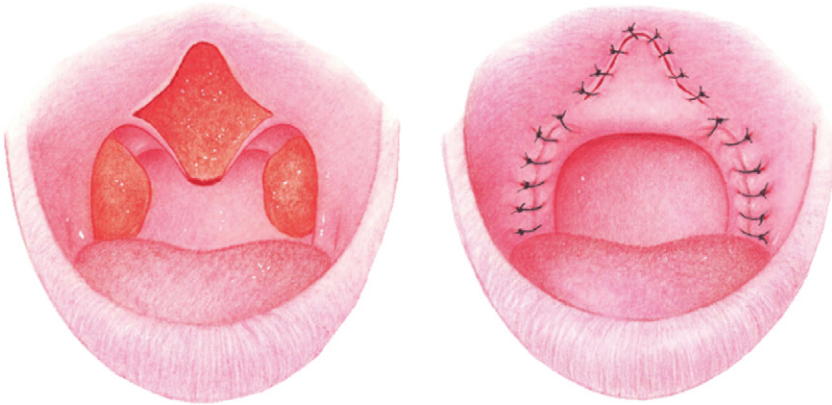

Fig. 3. Uvulopalatal flap. A modification of Fujita's uvulopalatopharyngoplasty involves retracting and advancing the uvula superiorly under the soft palate without removal.

(see [Table 3](#)).^{74,75,134} A recent retrospective analysis of the Mayo Clinic experience found a similar UPPP cure rate of 24%.²⁰⁸ Predictors of surgical cure in this analysis included younger age, lower preoperative BMI and AHI. Unfortunately, most patients with initial improvement in AHI after UPPP have recurrence within 5 years of therapy.²⁰⁹ Fortunately, UPPP likely confers a mortality benefit in CPAP intolerant

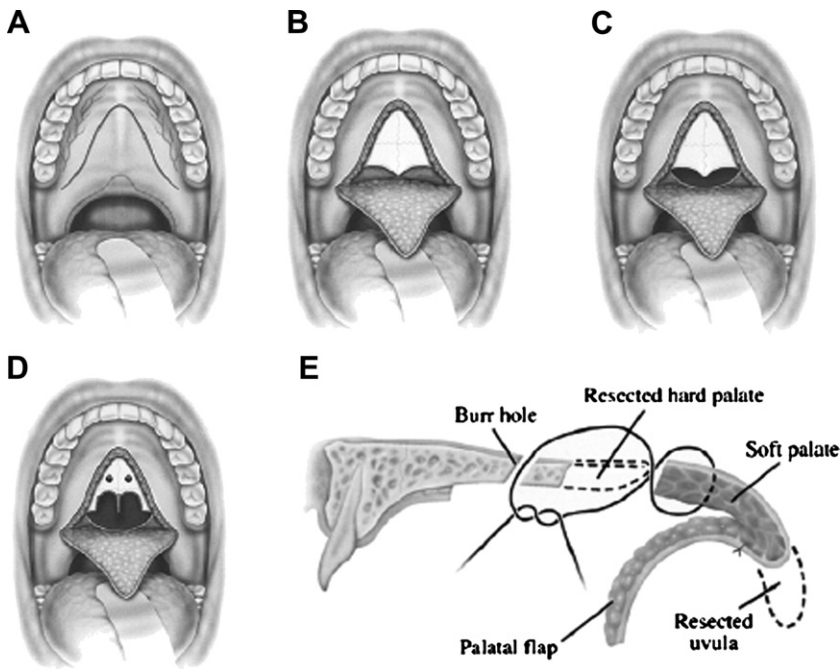


Fig. 4. Transpalatal advancement pharyngoplasty. Woodson's transpalatal advancement pharyngoplasty combines a uvulopalatopharyngoplasty with soft palate advancement. (Reproduced from Friedman M, Schalch P. Surgery of the palate and oropharynx. *Otolaryngol Clin N Am* 2007;40:840; with permission from Elsevier.)

patients (compared with no treatment), even when most patients do not obtain surgical cure.^{210–212} However, because UPPP is likely to eliminate snoring but will often leave residual OSA causing silent apnea, all patients must have postoperative sleep studies to rule out persistent disease.

UPPP is generally more effective at reducing apneas than hypopneas,^{75,193} and is most effective in patients with primarily oropharyngeal obstruction (as opposed to hypopharyngeal abnormalities).^{70,193} However, using fiberoptic endoscopy to select patients with predominantly soft palate pharyngeal collapse during a Müller maneuver has shown variable improvement in surgical success (45%–85%).^{213–216} Although the efficacy to cure OSA is suboptimal, UPPP may be useful in lowering positive airway pressure requirements, thus improving CPAP compliance in select patients.²¹⁷ However, UPPP may promote air leak during future CPAP therapy,^{218,219} although a recent study disputes this finding.²²⁰ Approximately 70% of patients are satisfied after UPPP.^{221,222}

Early postoperative complications include wound dehiscence, hemorrhage, infection, and transient velopharyngeal incompetence (eg, nasal regurgitation and hypernasal speech).¹⁹⁵ Late postoperative complications include pharyngeal discomfort (eg, dryness, tightness), postnasal secretions, dysphagia, inability to initiate swallowing, odynophagia, nasopharyngeal stenosis, taste and speech disturbances, tongue numbness, and rarely permanent velopharyngeal incompetence. Up to 30% of patients complain of persistent although generally mild dysphagia.^{223–226} A systematic review reported a serious complication rate of 2.5% with 30 deaths (~0.2% mortality) and persistent side effects in 58% (31% nasal regurgitation, 13% voice changes, 5% taste disturbances) of patients after UPPP.¹²⁷ Voice changes are generally mild.²²⁷ A recent study noted that health-related quality of life measurements were better in patients with post-UPPP side effects compared with CPAP users (independent of compliance) with side effects.²²⁸

Procedures that Modify or Advance the Skeletal or Soft Tissue Structures

Genioglossus advancement

In the mid-1980s, Riley and colleagues^{229,230} first described genioglossus muscle advancement (GA) to improve the posterior airspace (eg, base of tongue). Their initial technique (a modified horizontal mandibular osteotomy) was later improved in 1986 to include a limited inferior parasagittal mandibular osteotomy (**Fig. 5**).^{230,231} Advancing the geniotubercle forward of the mandible positions the genioglossus and geniohyoid muscles anteriorly, thus enlarging the retrolingual space.²³² Variations of this procedure include mortised genioplasty, circle genioplasty, and standard genioplasty.^{233,234} Four case series describing 91 patients with severe OSA (mean AHI 54/h) undergoing GA as sole treatment report a surgical success rate of 67% (range 39%–79%) (see **Table 3**).¹³⁴ GA is generally used within a multimodality approach to treat base of tongue obstructions.

Hyoid myotomy and suspension

In the mid-1980s, Riley and colleagues^{229,230,235} developed a hyoid suspension procedure to improve the posterior (retrolingual) airspace (**Fig. 6**). The hyoid bone is located in the anterior neck below the mandible and is involved in maintaining upper airway patency.^{236,237} Several protocols have been described including hyoid to mandibular suspension (hypomandibular), hyoid to thyroid cartilage suspension (thyrohyoid), and hyoid expansion.²³⁸ Hyoid suspension is generally used within a multimodality approach^{238–240} with a surgical success rate (performed with previous or concurrent palate surgery) of approximately 50% (see **Table 3**).¹³⁴ However, there

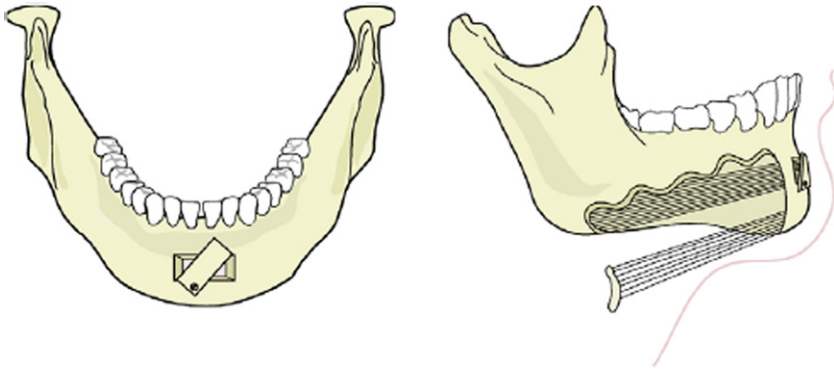


Fig. 5. Mandibular osteotomy with genioglossus advancement. Limited inferior parasagittal mandibular osteotomy (eg, a rectangular window in the symphyseal bone with advancement, rotation, and immobilization of the geniotubercle) with advancement of the genioglossus and geniohyoid muscles. (Reproduced from Li KL. Hypopharyngeal airway surgery. *Otolaryngol Clin N Am* 2007;40:848; with permission from Elsevier.)

are no reliable preoperative predictors for success with hyoid suspension following UPPP.²⁴¹ Furthermore, combining genioglossus advancement with hyoid suspension marginally improves surgical success (~55%) (see [Table 3](#)),¹³⁴ and 1 study of hyoid suspension with radiofrequency of the tongue reported a surgical success rate of only 49%.²⁴² Excessive daytime sleepiness generally improves after hyoid suspension, albeit inconsistently.^{239,243–246}

Mandibular (or maxillary) distraction osteogenesis

Distraction osteogenesis (DO) of the mandible (and/or maxilla) involves bilateral segmental osteotomies followed by gradual distraction (via an expandable intra- or extraoral device) with subsequent ossification and bone lengthening.²⁴⁷ DO of the mandible effectively improves OSA in children with genetic craniofacial abnormalities.^{248–251} One study of 5 otherwise normal adults with OSA reported a decrease in AHI from 49/h to 7/h after mandibular (or maxillary) DO.²⁴⁷ However, this study

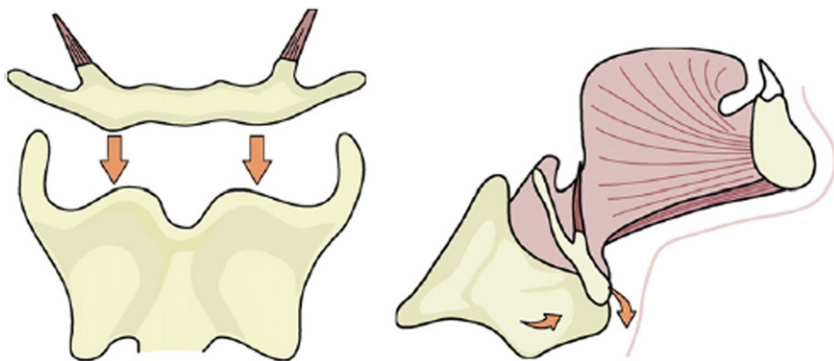


Fig. 6. Hyoid myotomy suspension. Hyoid to thyroid cartilage suspension (thyrohyoid) involves isolation of the hyoid bone that is advanced, sutured, and immobilized to the thyroid cartilage. (Reproduced from Li KL. Hypopharyngeal airway surgery. *Otolaryngol Clin N Am* 2007;40:848; with permission from Elsevier.)

reported several problems with DO including the technical difficulty of the procedure, a high risk of malocclusion, subsequent need for orthodontics because of limited control of the distractor vector, and poor patient satisfaction (eg, treatment required 4 months of stabilization via intraoral arch bars that inhibited mastication and speech).

Maxillomandibular advancement

In 1979, Kuo and colleagues²⁰ reported improvements in polysomnographic parameters and subjective sleepiness in 3 patients with OSA with retrognathia after mandibular osteotomy with advancement. Similar improvements in OSA parameters after mandibular advancement were noted by others.^{21,252,253} However, by the mid-1980s, mandibular advancement alone was largely supplanted by combined maxillary and mandibular advancement to preserve the maxilla-mandibular relationship and from the recognition that the physiologic cause for OSA is often from concomitant mandibular and maxillary deficiency.^{235,254} Mandibular osteotomy with advancement is currently relegated to the treatment of mandibular hypoplasia in syndromic children with OSA.²⁵⁵

Maxillomandibular advancement (MMA) involves Le Fort I maxillary and bilateral sagittal ramus split mandibular osteomies with advancement of the maxilla and mandible followed by rigid fixation (**Fig. 7**).²⁵⁶ Generally, the maxilla is advanced first, with the mandible advanced into occlusion. Combined MMA alleviates pharyngeal obstruction by expanding the skeletal framework that the tongue and other soft tissue

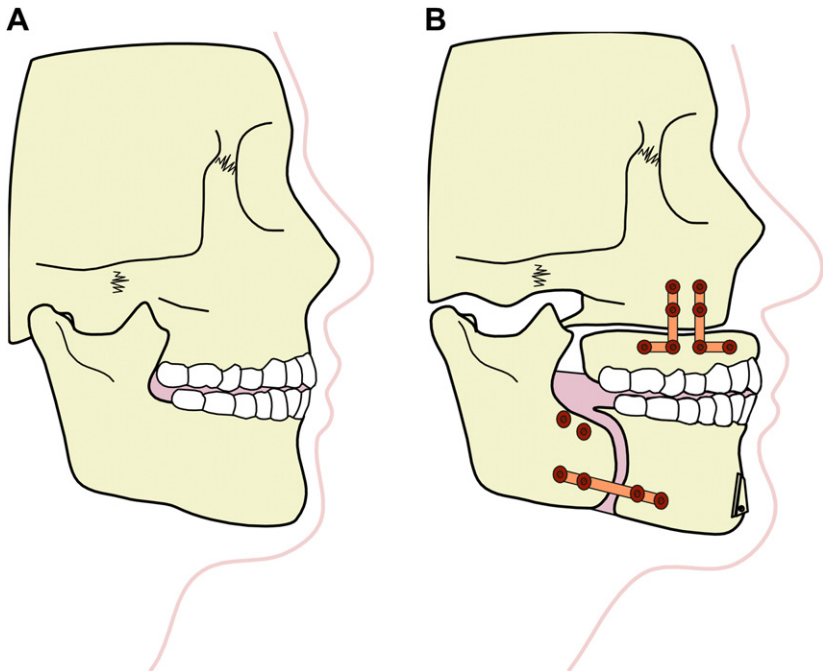


Fig. 7. Maxillomandibular advancement. Before (A) and after (B) maxillomandibular advancement surgery via a Le Fort I osteotomy (with rigid plate fixation) and bilateral sagittal split mandibular osteotomy (with bicortical screw fixation). (Reproduced and modified from Li KL. Hypopharyngeal airway surgery. *Otolaryngol Clin N Am* 2007;40:849; with permission from Elsevier.)

structures attach to resulting in reduced upper-airway restriction and collapsibility during inspiration.²⁵⁷ Mandibular advancement advances the tongue and suprahyoid muscles.²⁵⁸ Maxillary advancement pulls forward the velum and velopharyngeal muscles,²⁵⁹ increases the nasopharyngeal and hypopharyngeal spaces,^{260,261} and increases alar width with a concomitant decrease in nasal airway resistance.^{262,263} Improvements in pharyngeal obstruction after MMA occur along the entire upper airway in the lateral and anteroposterior dimensions.^{27,264}

MMA is the most effective craniofacial surgery (in adults) for the treatment of OSA.^{76,265} A recent meta-analysis of 22 studies (627 subjects with OSA) determined that MMA is highly effective with a mean decrease in AHI from 64/h to 11/h ($P < .001$) with pooled surgical success and cure (AHI $< 5/h$) rates of 86% and 43%, respectively (see **Table 3**).²⁶⁶ Predictors of increased surgical success include younger age, lower preoperative AHI and BMI, and greater degree of maxillary advancement.²⁶⁶ Furthermore, MMA maintains its efficacy at long-term follow-up.^{267,268} Following MMA, most patients report improvements in health-related quality of life, depression, excessive daytime sleepiness, memory impairment, and hypertension.^{267,269–279} Candidates for MMA include adults and adolescents (after the cranial sutures have completely ossified) with maxillomandibular insufficiency or those who have failed previous therapeutic interventions for OSA.^{256,265} In addition, MMA is successful in patients with obesity or with severe OSA.²⁶⁵

MMA is generally safe with no reported deaths and a major complication rate of only 1.0% (mostly cardiac causes).²⁶⁶ Between 0% and 15% of MMA patients experience mild surgical relapse without apparent symptoms or worsening of the AHI.^{267,280–282} However, relapse is not associated with the degree of mandibular advancement.^{281,283,284} Mild malocclusion occurs in up to 44% of patients and is generally treatable with prosthetics or minor occlusional equilibration.^{267,285} Transient facial paresthesia (ie, inferior alveolar nerve neurosensory deficits) after MMA is common ($\sim 100\%$), although most cases (86%) resolve within 1 year.²⁶⁶ Velopharyngeal insufficiency or mild speech and swallowing deficits are rarely reported after MMA.^{272,280,286,287} Patients completing sequential phase I (UPPP) and phase II (MMA) surgery generally report less pain after MMA compared with phase I surgery.^{287,288} The average hospitalization time is less than 1 week with most patients returning to work within 4 to 10 weeks after surgery.^{275,288}

After MMA, most patients report a positive perception of facial aesthetics.²⁸⁹ Li and colleagues^{289,290} noted 6 months after surgery that 50% of patients report a younger facial appearance, 36% report a more attractive appearance, and only 9% report a less attractive facial appearance. In this same study, all patients (100%) reported satisfaction with the surgical outcome. Three other studies reported no patients (0%) were bothered by postoperative facial aesthetics.^{272,274,286} Modified MMA techniques, particularly using counterclockwise rotation and pre- or postsurgical orthodontics, have been developed to prevent maxillary protrusion and improve aesthetics.²⁹¹

Maxillomandibular expansion

Surgically assisted maxillomandibular expansion (MME; limited osteotomy at Le Fort I level and midline maxilla followed by expansion) may be an effective therapy for OSA in adults (**Fig. 8**).^{292,293} One study ($n = 6$) reported improvements in excessive daytime sleepiness and OSA (AHI from 13/h to 5/h) at a mean follow-up of 18 months after an average mandibular and maxillary expansion of 9.5 and 10.3 mm, respectively.²⁹³ The investigators concluded that nonobese adolescents or young adults with mild OSA and who require orthodontic treatment are ideal candidates for MME.

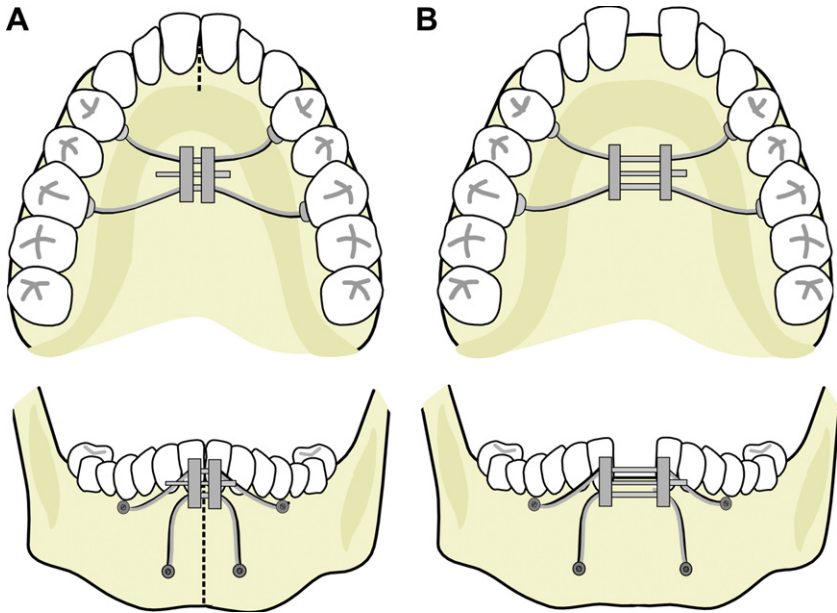


Fig. 8. Maxillomandibular expansion. Before (A) and after (B) surgically assisted maxillo-mandibular expansion with Le Fort I osteotomy and pterygomaxillary (midline) dysjunction followed by expansion using an orthodontic screwlike device.

Pillar palatal implants

This minimally invasive procedure involves inserting matchstick size rigid polyester implants via a hollow needle delivery tool into the soft palate.²⁹⁴ Pillar implants improve snoring by stiffening the soft palate, but their effect on OSA is less clear and the long-term benefits on OSA are unknown.^{295–298} In a prospective nonrandomized trial of 25 patients with mild-moderate OSA (mean AHI 16.2/h), the surgical success and cure rates were 40% and 28%, respectively.²⁹⁶ Friedman and colleagues²⁹⁵ in a randomized trial of 62 nonobese patients with mild-moderate OSA (mean AHI 23.5/h), found a statistically significant improvement in AHI after pillar implants (compared with placebo procedure), although the mean AHI after surgery was still within the moderate range (mean AHI 15.9/h) with a surgical success rate of 45%. Complications are rare, but include infrequent postinsertion extrusion.

Rapid maxillary expansion

In 1860, Angell²⁹⁹ reported the first use of rapid maxillary expansion (RME) to correct a transverse maxillary deficiency. RME is currently a common orthodontic procedure to correct dental crowding and to ensure a normal mandibular-maxillary relationship.³⁰⁰ RME expands the mid-palatal suture via a screw-type orthodontic appliance resulting in an increase in the upper transverse width.³⁰⁰ RME induces normal tongue positioning via palatal widening and flattening, downward and forward displacement of the maxilla, widening of the nasal vault (with subsequent decreased resistance and improvement in nasal breathing) and transforms a class III to a class I prognathoid position.^{301–312} After 2 to 4 weeks of expansion, a 2- to 6-month retention period is necessary while ossification between the expanded mid-palatal suture line is completed.³⁰⁴ The suture line in prepubertal children is cartilaginous and easily

separated, but horizontal osteotomy is often required in adults (whose suture line is generally ossified) before RME.³¹³

Children without known OSA often report quieter nighttime breathing, reduced snoring, and improved sleep quality after RME.^{303,314,315} In 1996, Palmisano and colleagues³¹⁶ reported the first use of RME to successfully treat OSA (AHI went from 22/h to 4/h) in a 22-year-old with maxillary constriction and a class I malocclusion. Subsequently, 3 studies evaluating RME in children with OSA ($n = 88$; mean expansion 6.2 ± 2.1 mm)^{181,317–319} reported a mean decrease in AHI from 11/h to 0.8/h after RME ($P < .001$) with subjective improvements in snoring, excessive daytime sleepiness, and behavioral problems (see [Table 3](#)).³²⁰ One study of 10 adults with OSA who received surgically assisted RME (mean expansion 12.1 mm) reported statistically significant improvements in AHI (19/h to 4/h; $P < .05$) with a 70% cure rate (AHI < 5 /h).³²¹

SINGLE-STAGE MULTIMODALITY APPROACH

Pharyngeal surgeries are often combined to address airway obstruction(s) at multiple levels (eg, nose, palate, tonsils, hypopharynx). Multilevel surgery may improve surgical success compared with single-site therapy.^{322–324} The most common single-stage multimodality procedure combines UPPP with a second procedure designed to improve the hypopharyngeal airway (eg, genioglossal advancement, hyoid suspension, base of tongue resection [uvulopalatopharyngoglossoplasty]). Lin and colleagues⁷⁴ in a meta-analysis of 58 studies emphasized the benefits of a multimodality approach reporting a surgical success rate of 66% (see [Table 3](#)).

Unfortunately, multimodality surgery does not always guarantee increased efficacy. A meta-analysis of hypopharyngeal surgery by Kezirian and Goldberg¹³⁴ concluded combination procedures such as genioglossus advancement with hyoid suspension or tongue radiofrequency treatment with tongue stabilization have lower surgical success rates and poorer AHI improvement compared with the same procedures performed alone.

STAGED SURGICAL PROTOCOL

The Riley-Powell-Stanford surgical protocol was developed to address the multilevel airway abnormalities that often contribute to OSA ([Fig. 9](#)).³²⁵ Phase 1 consists of interventions directed at the site(s) of obstruction in the nasal, pharyngeal, or hypopharyngeal regions (eg, UPPP for oropharyngeal obstruction, genioglossus advancement for hypopharyngeal obstruction).³²⁶ Approximately 6 months after surgery, repeat polysomnography is performed and patients who do not obtain surgical success (or cure), proceed to phase 2 surgery consisting of MMA.³²⁷ The Stanford group reports a staged protocol surgical success rate of 95%.³²⁵

However, the appropriateness of the staged protocol has been questioned. Wagner and colleagues²⁷⁴ noted that two-thirds of their MMA failures had previous phase 1 surgery (eg, UPPP). Others have proposed that MMA should be performed first with UPPP (or other palatal and hypopharyngeal surgeries) performed in those patients with residual OSA.²⁶⁸ A review by the American Sleep Disorders Association found insufficient evidence to assess the efficacy of a staged versus primary MMA surgical approach.⁷⁵ A recent meta-analysis of MMA found that patients with previous UPPP before MMA were less likely to obtain surgical cure (25% vs 45%; $P = .002$) compared with those without previous surgery following MMA.²⁶⁶ However, this finding was likely confounded by greater obesity and more severe OSA in patients with previous palatal surgery. The investigators concluded that, “further research is needed to identify

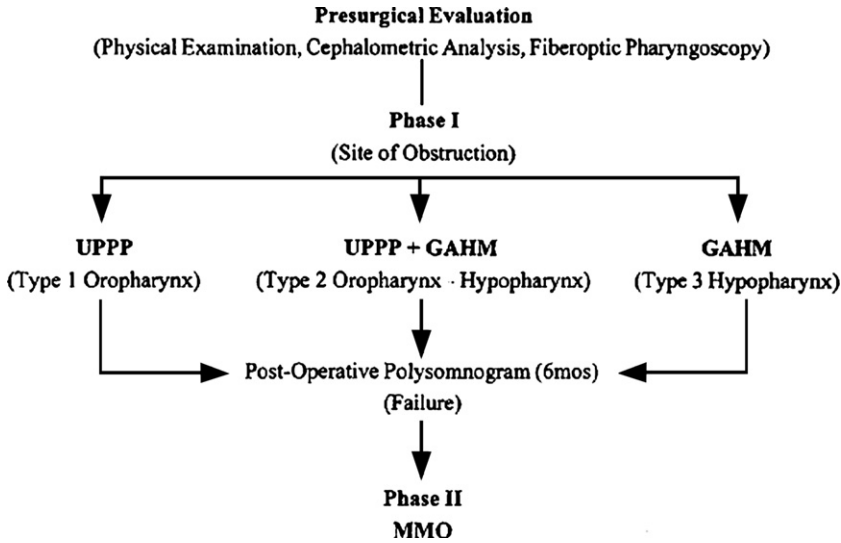


Fig. 9. Riley-Powell-Stanford surgical staged protocol. (Reproduced from Riley RW, Powell ND, Li KK, et al. Surgery and obstructive sleep apnea: long-term clinical outcomes. *Otolaryngol Head Neck Surg* 2000;122:416; with permission from Mosby-Year Book, Inc.)

preoperative patient and clinical characteristics to select those patients who would benefit most from a staged versus primary MMA surgical approach.²⁶⁶

BARIATRIC SURGERY

Approximately 65% of adults in the United States are overweight (BMI >25 kg/m²) and more than 30% are obese (BMI >30 kg/m²).³²⁸ Surgically induced weight loss was first performed in 1967³²⁹ and is now a preferred weight reduction modality for morbidly obese individuals (BMI ≥40 kg/m²) with more than 100,000 procedures performed annually in the United States.³³⁰ Bariatric surgery is generally safe, results in marked and sustained weight loss, and is associated with improved mortality compared with conventional weight-loss strategies.^{331–333} Procedures are classified as predominantly malabsorptive (eg, biliopancreatic diversion, duodenal switch, jejunioileal bypass), predominantly restrictive (eg, vertical banded gastroplasty, adjustable gastric banding, sleeve gastrectomy, intragastric balloon), or combined malabsorptive and restrictive (eg, Roux-en-Y gastric bypass, sleeve gastrectomy with duodenal switch).³³³ Candidates for bariatric surgery should fulfill the 1991 National Institutes of Health guideline criteria that includes a BMI ≥40 kg/m², or a BMI ≥35 kg/m² with associated comorbidity (eg, OSA).^{334,335}

Obesity is a leading cause of OSA with an estimated 40% prevalence in obese persons (BMI ≥30 kg/m²).³³⁶ A 10% increase in BMI results in a 32% increase in the AHI.³³⁶ Mild to moderate weight reduction can improve sleep apnea and daytime sleepiness.^{336,337} Two recent meta-analyses have evaluated the effectiveness of bariatric surgery to treat OSA.^{338,339} Holty and colleagues³³⁹ found OSA to be highly prevalent (79%) among bariatric candidates (of these 76% had moderate to severe disease), but exceedingly underdiagnosed (only 30% preoperatively). There were no identifiable presurgical symptoms or clinical findings predictive of polysomnographically confirmed OSA.³³⁹ Greenberg and colleagues³³⁸ noted that after surgically

induced weight loss (BMI went from 55 to 38 kg/m²), the AHI improved from 55 to 16/h (see [Table 3](#)). However, more than 50% of bariatric recipients with preoperative OSA have residual disease despite weight loss.³³⁹ Predictors of greater AHI reduction (or OSA cure) included younger age, but not symptom improvement (eg, excessive daytime sleepiness) or the degree of BMI change.^{338,339} In addition, initial improvements in AHI appeared to wane at follow-up despite maintained weight loss.³³⁹

SUMMARY

OSA is a prevalent condition associated with increased morbidity and mortality. Although CPAP is the preferred treatment, poor compliance is common. Fortunately, several surgical treatments exist to address a variety of pharyngeal abnormalities. Case series suggest that MMA has the highest surgical efficacy (86%) and cure rate (43%). Morbidly obese individuals may benefit from bariatric surgery, although less than 50% are cured after surgically induced weight loss. Soft palate surgical techniques are less successful, with UPPP having an OSA surgical success and cure rate of 50% and 16%, respectively. Patients may benefit from a multimodality surgical approach. In conclusion, individuals intolerant of CPAP may benefit from surgical therapies that address their particular airway obstruction(s). However, further research is needed to more thoroughly assess clinical outcomes (eg, quality of life, morbidity), better identify key preoperative patient and clinical characteristics that predict success, and confirm long-term effectiveness of surgical modalities to treat OSA.

ACKNOWLEDGMENTS

We thank Kasey K. Li, MD, DDS, for graciously providing the figures illustrating tonsillectomy, uvulopalatal flap, and maxillomandibular expansion procedures.

REFERENCES

1. Guilleminault C, Tilkian A, Dement WC. The sleep apnea syndromes. *Annu Rev Med* 1976;27:465–84.
2. Young T, Finn L, Peppard PE, et al. Sleep disordered breathing and mortality: eighteen-year follow-up of the Wisconsin sleep cohort. *Sleep* 2008;31(8):1071–8.
3. Duran J, Esnaola S, Rubio R, et al. Obstructive sleep apnea-hypopnea and related clinical features in a population-based sample of subjects aged 30 to 70 yr. *Am J Respir Crit Care Med* 2001;163(3 Pt 1):685–9.
4. Sogut A, Altin R, Uzun L, et al. Prevalence of obstructive sleep apnea syndrome and associated symptoms in 3–11-year-old Turkish children. *Pediatr Pulmonol* 2005;39(3):251–6.
5. Brunetti L, Rana S, Lospalluti ML, et al. Prevalence of obstructive sleep apnea syndrome in a cohort of 1,207 children of southern Italy. *Chest* 2001;120(6):1930–5.
6. Redline S, Tishler PV, Schluchter M, et al. Risk factors for sleep-disordered breathing in children. Associations with obesity, race, and respiratory problems. *Am J Respir Crit Care Med* 1999;159(5 Pt 1):1527–32.
7. Lumeng JC, Chervin RD, Lumeng JC, et al. Epidemiology of pediatric obstructive sleep apnea. *Proc Am Thorac Soc* 2008;5(2):242–52.
8. Young T, Peppard PE, Gottlieb DJ. Epidemiology of obstructive sleep apnea: a population health perspective. *Am J Respir Crit Care Med* 2002;165(9):1217–39.

9. Sullivan CE, Issa FG, Berthon-Jones M, et al. Reversal of obstructive sleep apnoea by continuous positive airway pressure applied through the nares. *Lancet* 1981;1(8225):862–5.
10. Indications and standards for use of nasal continuous positive airway pressure (CPAP) in sleep apnea syndromes. *Am J Respir Crit Care Med* 1994;150:1738–45.
11. Giles TL, Lasserson TJ, Smith BJ, et al. Continuous positive airways pressure for obstructive sleep apnoea in adults. *Cochrane Database Syst Rev* 2006;(3):CD001106.
12. Gay P, Weaver T, Loubé D, et al. Evaluation of positive airway pressure treatment for sleep related breathing disorders in adults. *Sleep* 2006;29(3):381–401.
13. Jenkinson C, Davies RJ, Mullins R, et al. Comparison of therapeutic and subtherapeutic nasal continuous positive airway pressure for obstructive sleep apnoea: a randomised prospective parallel trial. *Lancet* 1999;353(9170):2100–5.
14. Weaver TE, Grunstein RR. Adherence to continuous positive airway pressure therapy: the challenge to effective treatment. *Proc Am Thorac Soc* 2008;5(2):173–8.
15. Engleman HM, Wild MR. Improving CPAP use by patients with sleep apnoea/hypopnoea syndrome (SAHS). *Sleep Med Rev* 2003;7(1):81–99.
16. Campos-Rodriguez F, Pena-Grinan N, Reyes-Nunez N, et al. Mortality in obstructive sleep apnea-hypopnea patients treated with positive airway pressure. *Chest* 2005;128(2):624–33.
17. Yaggi HK, Concato J, Kernan WN, et al. Obstructive sleep apnea as a risk factor for stroke and death. *N Engl J Med* 2005;353(19):2034–41.
18. Rapoport DM, Sorkin B, Garay SM, et al. Reversal of the “Pickwickian syndrome” by long-term use of nocturnal nasal-airway pressure. *N Engl J Med* 1982;307(15):931–3.
19. Kuhlo W, Doll E, Frank MC. [Successful management of Pickwickian Syndrome using long term tracheostomy]. *Dtsch Med Wochenschr* 1969;94(24):1286–90 [in German].
20. Kuo PC, West RA, Bloomquist DS, et al. The effect of mandibular osteotomy in three patients with hypersomnia sleep apnea. *Oral Surg Oral Med Oral Pathol* 1979;48(5):385–92.
21. Bear SE, Priest JH. Sleep apnea syndrome: correction with surgical advancement of the mandible. *J Oral Surg* 1980;38(7):543–9.
22. Ikematsu T. [Study of snoring. 4th report]. *J Jpn Otol Rhinol Laryngol Soc* 1964;64:434–5 [in Japanese].
23. Fujita S, Conway W, Zorick F, et al. Surgical correction of anatomic abnormalities in obstructive sleep apnea syndrome: uvulopalatopharyngoplasty. *Otolaryngol Head Neck Surg* 1981;89(6):923–34.
24. Conway W, Fujita S, Zorick F, et al. Uvulo-palato-pharyngoplasty in treatment of upper airway sleep apnea [abstract]. *Am Rev Respir Dis* 1980;121(Suppl):121.
25. Johns FR, Strollo PJ Jr, Buckley M, et al. The influence of craniofacial structure on obstructive sleep apnea in young adults. *J Oral Maxillofac Surg* 1998;56(5):596–602.
26. Rojewski TE, Schuller DE, Clark RW, et al. Videoendoscopic determination of the mechanism of obstruction in obstructive sleep apnea. *Otolaryngol Head Neck Surg* 1984;92(2):127–31.
27. Fairburn SC, Waite PD, Vilos G, et al. Three-dimensional changes in upper airways of patients with obstructive sleep apnea following maxillomandibular advancement. *J Oral Maxillofac Surg* 2007;65(1):6–12.

28. Suto Y, Matsuo T, Kato T, et al. Evaluation of the pharyngeal airway in patients with sleep apnea: value of ultrafast MR imaging. *AJR Am J Roentgenol* 1993; 160(2):311–4.
29. Nishino T. Physiological and pathophysiological implications of upper airway reflexes in humans. *Jpn J Physiol* 2000;50(1):3–14.
30. Pierce RJ, Worsnop CJ. Upper airway function and dysfunction in respiration. *Clin Exp Pharmacol Physiol* 1999;26(1):1–10.
31. Brouillette RT, Thach BT. A neuromuscular mechanism maintaining extrathoracic airway patency. *J Appl Physiol* 1979;46(4):772–9.
32. Remmers JE, deGroot WJ, Sauerland EK, et al. Pathogenesis of upper airway occlusion during sleep. *J Appl Physiol* 1978;44(6):931–8.
33. Petrof BJ, Hendricks JC, Pack AI. Does upper airway muscle injury trigger a vicious cycle in obstructive sleep apnea? A hypothesis. *Sleep* 1996;19(6): 465–71.
34. Schwab RJ, Geftter WB, Hoffman EA, et al. Dynamic upper airway imaging during awake respiration in normal subjects and patients with sleep disordered breathing. *Am Rev Respir Dis* 1993;148(5):1385–400.
35. Kushida CA, Efron B, Guilleminault C. A predictive morphometric model for the obstructive sleep apnea syndrome. *Ann Intern Med* 1997;127(8 Pt 1):581–7.
36. Schwab RJ, Gupta KB, Geftter WB, et al. Upper airway and soft tissue anatomy in normal subjects and patients with sleep-disordered breathing. Significance of the lateral pharyngeal walls. *Am J Respir Crit Care Med* 1995;152(5 Pt 1): 1673–89.
37. Rodenstein DO, Doods G, Thomas Y, et al. Pharyngeal shape and dimensions in healthy subjects, snorers, and patients with obstructive sleep apnoea. *Thorax* 1990;45(10):722–7.
38. Lee SH, Choi JH, Shin C, et al. How does open-mouth breathing influence upper airway anatomy? *Laryngoscope* 2007;117(6):1102–6.
39. Chen W, Kushida CA. Nasal obstruction in sleep-disordered breathing. *Otolaryngol Clin North Am* 2003;36(3):437–60.
40. Konno A, Togawa K, Hoshino T. The effect of nasal obstruction in infancy and early childhood upon ventilation. *Laryngoscope* 1980;90(4):699–707.
41. Olsen KD, Kern EB, Westbrook PR. Sleep and breathing disturbance secondary to nasal obstruction. *Otolaryngol Head Neck Surg* 1981;89(5):804–10.
42. Zwillich CW, Pickett C, Hanson FN, et al. Disturbed sleep and prolonged apnea during nasal obstruction in normal men. *Am Rev Respir Dis* 1981;124(2): 158–60.
43. Rubin A, Phillipson E, Lavie P. The effects of airway anesthesia on breathing in sleep [abstract]. *Chest* 1983;84:337.
44. Patil SP, Schneider H, Marx JJ, et al. Neuromechanical control of upper airway patency during sleep. *J Appl Physiol* 2007;102(2):547–56.
45. Guilleminault C, Huang YS, Kirisoglu C, et al. Is obstructive sleep apnea syndrome a neurological disorder? A continuous positive airway pressure follow-up study. *Ann Neurol* 2005;58(6):880–7.
46. Kuna ST, Bedi DG, Ryckman C. Effect of nasal airway positive pressure on upper airway size and configuration. *Am Rev Respir Dis* 1988;138(4):969–75.
47. Edstrom L, Larsson H, Larsson L. Neurogenic effects on the palatopharyngeal muscle in patients with obstructive sleep apnoea: a muscle biopsy study. *J Neurol Neurosurg Psychiatr* 1992;55(10):916–20.
48. Woodson BT, Garancis JC, Toohill RJ. Histopathologic changes in snoring and obstructive sleep apnea syndrome. *Laryngoscope* 1991;101(12 Pt 1):1318–22.

49. McGinley BM, Schwartz AR, Schneider H, et al. Upper airway neuromuscular compensation during sleep is defective in obstructive sleep apnea. *J Appl Physiol* 2008;105(1):197–205.
50. Fregosi RF, Quan SF, Morgan WL, et al. Pharyngeal critical pressure in children with mild sleep-disordered breathing. *J Appl Physiol* 2006;101(3):734–9.
51. Marcus CL, Katz ES, Lutz J, et al. Upper airway dynamic responses in children with the obstructive sleep apnea syndrome. *Pediatr Res* 2005;57(1):99–107.
52. Troell RJ, Riley RW, Powell NB, et al. Surgical management of the hypopharyngeal airway in sleep disordered breathing. *Otolaryngol Clin North Am* 1998;31(6):979–1012.
53. Powell NB, Riley RW, Guilleminault C, et al. Obstructive sleep apnea, continuous positive airway pressure, and surgery. *Arch Otolaryngol Head Neck Surg* 1988;99(4):362–9.
54. Guilleminault C, Partinen M, Praud JP, et al. Morphometric facial changes and obstructive sleep apnea in adolescents. *J Pediatr* 1989;114(6):997–9.
55. Rondeau BH. Importance of diagnosing and treating orthodontic and orthopedic problems in children. *Funct Orthod* 2004;21(3):4.
56. Guilleminault C, Lee JH, Chan A, et al. Pediatric obstructive sleep apnea syndrome. *Arch Pediatr Adolesc Med* 2005;159(8):775–85.
57. Pirila K, Tahvanainen P, Huggare J, et al. Sleeping positions and dental arch dimensions in children with suspected obstructive sleep apnea syndrome. *Eur J Oral Sci* 1995;103(5):285–91.
58. Pirila-Parkkinen K, Pirttiniemi P, Nieminen P, et al. Dental arch morphology in children with sleep-disordered breathing. *Eur J Orthod* 2009;31(2):160–7.
59. Smith RM, Gonzalez C. The relationship between nasal obstruction and craniofacial growth. *Pediatr Clin North Am* 1989;36(6):1423–34.
60. Bresolin D, Shapiro PA, Shapiro GG, et al. Mouth breathing in allergic children: its relationship to dentofacial development. *Am J Orthod Dentofacial Orthop* 1983;83(4):334–40.
61. Subtelny JD. Oral respiration: facial maldevelopment and corrective dentofacial orthopedics. *Angle Orthod* 1980;50(3):147–64.
62. Kerr WJ, McWilliam JS, Linder-Aronson S. Mandibular form and position related to changed mode of breathing—a five-year longitudinal study. *Angle Orthod* 1989;59(2):91–6.
63. Vargervik K, Harvold EP. Experiments on the interaction between orofacial function and morphology. *Ear Nose Throat J* 1987;66(5):201–8.
64. Miller AJ, Vargervik K, Chierici G. Experimentally induced neuromuscular changes during and after nasal airway obstruction. *Am J Orthod Dentofacial Orthop* 1984;85(5):385–92.
65. Tomer BS, Harvold EP. Primate experiments on mandibular growth direction. *Am J Orthod Dentofacial Orthop* 1982;82(2):114–9.
66. Harvold EP, Tomer BS, Vargervik K, et al. Primate experiments on oral respiration. *Am J Orthod Dentofacial Orthop* 1981;79(4):359–72.
67. Harvold EP, Vargervik K, Chierici G. Primate experiments on oral sensation and dental malocclusions. *Am J Orthod Dentofacial Orthop* 1973;63(5):494–508.
68. Harvold EP, Chierici G, Vargervik K. Experiments on the development of dental malocclusions. *Am J Orthod Dentofacial Orthop* 1972;61(1):38–44.
69. Arens R, McDonough JM, Costarino AT, et al. Magnetic resonance imaging of the upper airway structure of children with obstructive sleep apnea syndrome. *Am J Respir Crit Care Med* 2001;164(4):698–703.

70. Riley R, Guilleminault C, Powell N, et al. Palatopharyngoplasty failure, cephalometric roentgenograms, and obstructive sleep apnea. *Otolaryngol Head Neck Surg* 1985;93(2):240–4.
71. Olszewska E, Sieskiewicz A, Rozycki J, et al. A comparison of cephalometric analysis using radiographs and craniofacial computed tomography in patients with obstructive sleep apnea syndrome: preliminary report. *Eur Arch Otorhinolaryngol* 2009;266(4):535–42.
72. Fujita S. Pharyngeal surgery for obstructive sleep apnea and snoring. In: Fairbanks DN, Fujita S, editors. *Snoring and obstructive sleep apnea*. 2nd edition. New York: Raven Press; 1994. p. 77–95.
73. Riley RW, Powell NB, Guilleminault C. Maxillary, mandibular, and hyoid advancement for treatment of obstructive sleep apnea: a review of 40 patients. *J Oral Maxillofac Surg* 1990;48(1):20–6.
74. Lin HC, Friedman M, Chang HW, et al. The efficacy of multilevel surgery of the upper airway in adults with obstructive sleep apnea/hypopnea syndrome. *Laryngoscope* 2008;118(5):902–8.
75. Sher AE, Schechtman KB, Piccirillo JF. The efficacy of surgical modifications of the upper airway in adults with obstructive sleep apnea syndrome. *Sleep* 1996;19(2):156–77.
76. Li KK. Surgical management of obstructive sleep apnea. *Clin Chest Med* 2003;24(2):365–70.
77. Elshaug AG, Moss JR, Southcott AM, et al. Redefining success in airway surgery for obstructive sleep apnea: a meta analysis and synthesis of the evidence. *Sleep* 2007;30(4):461–7.
78. Valero A, Alroy G. Hypoventilation in acquired micrognathia. *Arch Intern Med* 1965;115:307–9.
79. Lugaresi E, Coccagna G, Mantovani M, et al. Effets de la tracheotomie dans les hypersomnies avec respiration periodique [Effects of tracheostomy in the hypersomnia with periodic breathing]. *Rev Neurol (Paris)* 1970;123:267–8 [in French].
80. Lugaresi E, Coccagna G, Mantovani M, et al. Effects of tracheostomy in two cases of hypersomnia with periodic breathing. *J Neurol Neurosurg Psychiatr* 1973;36(1):15–26.
81. Guilleminault C, Simmons FB, Motta J, et al. Obstructive sleep apnea syndrome and tracheostomy. Long-term follow-up experience. *Arch Intern Med* 1981;141(8):985–8.
82. Campanini A, De Vito A, Frassinetti S, et al. Role of skin-lined tracheotomy in obstructive sleep apnoea syndrome: personal experience. *Acta Otorhinolaryngol Ital* 2004;24(2):68–74.
83. Katsantonis GP, Schweitzer PK, Branham GH, et al. Management of obstructive sleep apnea: comparison of various treatment modalities. *Laryngoscope* 1988;98(3):304–9.
84. Borowiecki BD, Sassin JF. Surgical treatment of sleep apnea. *Arch Otolaryngol Head Neck Surg* 1983;109(8):508–12.
85. Stradling JR. Avoidance of tracheostomy in sleep apnoea syndrome. *BMJ* 1982;285(6339):407–8.
86. Haapaniemi JJ, Laurikainen EA, Halme P, et al. Long-term results of tracheostomy for severe obstructive sleep apnea syndrome. *ORL J Otorhinolaryngol Relat Spec* 2001;63(3):131–6.
87. Kim SH, Eisele DW, Smith PL, et al. Evaluation of patients with sleep apnea after tracheotomy. *Arch Otolaryngol Head Neck Surg* 1998;124(9):996–1000.

88. Fletcher EC, Miller J, Schaaf JW, et al. Urinary catecholamines before and after tracheostomy in patients with obstructive sleep apnea and hypertension. *Sleep* 1987;10(1):35–44.
89. Guilleminault C, Cumiskey J. Progressive improvement of apnea index and ventilatory response to CO₂ after tracheostomy in obstructive sleep apnea syndrome. *Am Rev Respir Dis* 1982;126(1):14–20.
90. Sugita Y, Wakamatsu H, Teshima Y, et al. Therapeutic effects of tracheostomy in two cases of hypersomnia with respiratory disturbance during sleep. *Folia Psychiatr Neurol Jpn* 1980;34(1):17–25.
91. Imes NK, Orr WC, Smith RO, et al. Retrognathia and sleep apnea: a life-threatening condition masquerading as narcolepsy. *JAMA* 1977;237(15):1596–7.
92. Rodman DM, Martin RJ. Tracheostomy tube failure in obstructive sleep apnea. *West J Med* 1987;147(1):41–3.
93. Fletcher EC, Brown DL. Nocturnal oxyhemoglobin desaturation following tracheostomy for obstructive sleep apnea. *Am J Med* 1985;79(1):35–42.
94. Jin K, Okabe S, Chida K, et al. Tracheostomy can fatally exacerbate sleep-disordered breathing in multiple system atrophy. *Neurology* 2007;68(19):1618–21.
95. Fletcher EC. Recurrence of sleep apnea syndrome following tracheostomy. A shift from obstructive to central apnea. *Chest* 1989;96(1):205–9.
96. Weitzman ED, Kahn E, Pollak CP. Quantitative analysis of sleep and sleep apnea before and after tracheostomy in patients with the hypersomnia-sleep apnea syndrome. *Sleep* 1980;3(3-4):407–23.
97. Glenn WW, Gee JB, Cole DR, et al. Combined central alveolar hypoventilation and upper airway obstruction. Treatment by tracheostomy and diaphragm pacing. *Am J Med* 1978;64(1):50–60.
98. Tilkian AG, Guilleminault C, Schroeder JS, et al. Sleep-induced apnea syndrome. Prevalence of cardiac arrhythmias and their reversal after tracheostomy. *Am J Med* 1977;63(3):348–58.
99. Hastie SJ, Prowse K, Perks WH, et al. Obstructive sleep apnoea during pregnancy requiring tracheostomy. *Aust N Z J Obstet Gynaecol* 1989;29(3 Pt 2):365–7.
100. Weitzman ED, Pollack CP, Borowiecki B. Hypersomnia-sleep apnea due to micrognathia. Reversal by tracheoplasty. *Arch Neurol* 1978;35(6):392–5.
101. Motta J, Guilleminault C, Schroeder JS, et al. Tracheostomy and hemodynamic changes in sleep-inducing apnea. *Ann Intern Med* 1978;89(4):454–8.
102. Bhimaraj A, Havaligi N, Ramachandran S. Rapid reduction of antihypertensive medications and insulin requirements after tracheostomy in a patient with severe obstructive sleep apnea syndrome. *J Clin Sleep Med* 2007;3(3):297–9.
103. Simmons FB, Guilleminault C, Dement WC, et al. Surgical management of airway obstructions during sleep. *Laryngoscope* 1977;87(3):326–38.
104. Van de Heyning PH, De Roeck J, Claes J, et al. [Tracheostomy in the sleep apnea syndrome]. *Acta Otorhinolaryngol Belg* 1984;38(5):489–502 [in French].
105. Conway WA, Victor LD, Magilligan DJ Jr, et al. Adverse effects of tracheostomy for sleep apnea. *JAMA* 1981;246(4):347–50.
106. Conway WA, Bower GC, Barnes ME. Hypersomnolence and intermittent upper airway obstruction. Occurrence caused by micrognathia. *JAMA* 1977;237(25):2740–2.
107. He J, Kryger MH, Zorick FJ, et al. Mortality and apnea index in obstructive sleep apnea. Experience in 385 male patients. *Chest* 1988;94(1):9–14.
108. Partinen M, Jamieson A, Guilleminault C. Long-term outcome for obstructive sleep apnea syndrome patients. Mortality. *Chest* 1988;94(6):1200–4.

109. Partinen M, Guilleminault C. Daytime sleepiness and vascular morbidity at seven-year follow-up in obstructive sleep apnea patients. *Chest* 1990;97(1):27–32.
110. Thatcher GW, Maisel RH. The long-term evaluation of tracheostomy in the management of severe obstructive sleep apnea. *Laryngoscope* 2003;113(2):201–4.
111. Fedok FG, Strauss M, Houck JR, et al. Further clinical experience with the sili-cone tracheal cannula in obstructive sleep apnea. *Otolaryngol Head Neck Surg* 1987;97(3):313–8.
112. Orsini MA, Conner GH, Cadieux RJ, et al. Clinical experience with the silicone tracheal cannula in obstructive sleep apnea. *Otolaryngol Head Neck Surg* 1984;92(2):132–5.
113. Gross ND, Cohen JL, Andersen PE, et al. ‘Defatting’ tracheotomy in morbidly obese patients. *Laryngoscope* 2002;112(11):1940–4.
114. Ashley MJ. Concerns of sleep apnea patients with tracheostomies. *West J Nurs Res* 1989;11(5):600–8.
115. Harmon JD, Morgan W, Chaudhary B. Sleep apnea: morbidity and mortality of surgical treatment. *South Med J* 1989;82(2):161–4.
116. Darrat I, Yaremchuk K. Early mortality rate of morbidly obese patients after tracheotomy. *Laryngoscope* 2008;118(12):2125–8.
117. Eliashar R, Goldfarb A, Gross M, et al. A permanent tube-free tracheostomy in a morbidly obese patient with severe obstructive sleep apnea syndrome. *Isr Med Assoc J* 2002;4(12):1156–7.
118. Campanini A, De Vito A, Frassinetti S, et al. Temporary tracheotomy in the surgical treatment of obstructive sleep apnea syndrome: personal experience. *Acta Otorhinolaryngol Ital* 2003;23(6):474–8.
119. Charuzi I, Peiser J, Ovnat A, et al. Removal of tracheostomy in a morbidly obese sleep apneic patient after gastric bypass. *Sleep* 1986;9(3):449–50.
120. Mickelson SA, Rosenthal L. Closure of permanent tracheostomy in patients with sleep apnea: a comparison of two techniques. *Otolaryngol Head Neck Surg* 1997;116(1):36–40.
121. Hickey SA, Ford GR, Evans JN, et al. Tracheostomy closure in restrictive respiratory insufficiency. *J Laryngol Otol* 1990;104(11):883–6.
122. Law JH, Barnhart K, Rowlett W, et al. Increased frequency of obstructive airway abnormalities with long-term tracheostomy. *Chest* 1993;104(1):136–8.
123. Verse T, Pirsig W, Zimmermann E. [Obstructive sleep apnea in older patients after the closure of a tracheostoma]. *Dtsch Med Wochenschr* 2000;125(6):137–41 [in German].
124. Verse T, Pirsig W. [Meta-analysis of laser-assisted uvulopalatopharyngoplasty. What is clinically relevant up to now?]. *Laryngorhinootologie* 2000;79(5):273–84 [in German].
125. Larrosa F, Hernandez L, Morello A, et al. Laser-assisted uvulopalatoplasty for snoring: does it meet the expectations? *Eur Respir J* 2004;24(1):66–70.
126. Ferguson KA, Heighway K, Ruby RR. A randomized trial of laser-assisted uvulopalatoplasty in the treatment of mild obstructive sleep apnea. *Am J Respir Crit Care Med* 2003;167(1):15–9.
127. Franklin KA, Anttila H, Axelsson S, et al. Effects and side-effects of surgery for snoring and obstructive sleep apnea—a systematic review. *Sleep* 2009;32(1):27–36.
128. Walker RP, Grigg-Damberger MM, Gopalsami C, et al. Laser-assisted uvulopalatoplasty for snoring and obstructive sleep apnea: results in 170 patients. *Laryngoscope* 1995;105(9 Pt 1):938–43.

129. Littner M, Hirshkowitz M, Davila D, et al. Practice parameters for the use of auto-titrating continuous positive airway pressure devices for titrating pressures and treating adult patients with obstructive sleep apnea syndrome. An American Academy of Sleep Medicine report. *Sleep* 2002;25(2):143–7.
130. Walker RP, Gopalsami C. Laser-assisted uvulopalatoplasty: postoperative complications. *Laryngoscope* 1996;106(7):834–8.
131. Terris DJ, Clerk AA, Norbash AM, et al. Characterization of postoperative edema following laser-assisted uvulopalatoplasty using MRI and polysomnography: implications for the outpatient treatment of obstructive sleep apnea syndrome. *Laryngoscope* 1996;106(2 Pt 1):124–8.
132. Fujita S, Woodson BT, Clark JL, et al. Laser midline glossectomy as a treatment for obstructive sleep apnea. *Laryngoscope* 1991;101(8):805–9.
133. Woodson BT, Fujita S. Clinical experience with lingualplasty as part of the treatment of severe obstructive sleep apnea. *Otolaryngol Head Neck Surg* 1992;107(1):40–8.
134. Kezirian EJ, Goldberg AN. Hypopharyngeal surgery in obstructive sleep apnea: an evidence-based medicine review. *Arch Otolaryngol Head Neck Surg* 2006;132(2):206–13.
135. Powell NB, Riley RW, Guilleminault C. Radiofrequency tongue base reduction in sleep-disordered breathing: a pilot study. *Otolaryngol Head Neck Surg* 1999;120(5):656–64.
136. Stuck BA, Maurer JT, Hein G, et al. Radiofrequency surgery of the soft palate in the treatment of snoring: a review of the literature. *Sleep* 2004;27(3):551–5.
137. Li KK, Powell NB, Riley RW, et al. Temperature-controlled radiofrequency tongue base reduction for sleep-disordered breathing: long-term outcomes. *Otolaryngol Head Neck Surg* 2002;127(3):230–4.
138. Stuck BA, Starzak K, Hein G, et al. Combined radiofrequency surgery of the tongue base and soft palate in obstructive sleep apnoea. *Acta Otolaryngol* 2004;124(7):827–32.
139. Fischer Y, Khan M, Mann WJ. Multilevel temperature-controlled radiofrequency therapy of soft palate, base of tongue, and tonsils in adults with obstructive sleep apnea. *Laryngoscope* 2003;113(10):1786–91.
140. Friedman M, Ibrahim H, Lee G, et al. Combined uvulopalatopharyngoplasty and radiofrequency tongue base reduction for treatment of obstructive sleep apnea/hypopnea syndrome. *Otolaryngol Head Neck Surg* 2003;129(6):611–21.
141. Riley RW, Powell NB, Li KK, et al. An adjunctive method of radiofrequency volumetric tissue reduction of the tongue for OSAS. *Otolaryngol Head Neck Surg* 2003;129(1):37–42.
142. Woodson BT, Steward DL, Weaver EM, et al. A randomized trial of temperature-controlled radiofrequency, continuous positive airway pressure, and placebo for obstructive sleep apnea syndrome. *Otolaryngol Head Neck Surg* 2003;128(6):848–61.
143. Stuck BA, Maurer JT, Verse T, et al. Tongue base reduction with temperature-controlled radiofrequency volumetric tissue reduction for treatment of obstructive sleep apnea syndrome. *Acta Otolaryngol* 2002;122(5):531–6.
144. Stuck BA, Maurer JT, Hormann K. [Tongue base reduction with radiofrequency energy in sleep apnea]. *HNO* 2001;49(7):530–7 [in German].
145. Woodson BT, Nelson L, Mickelson S, et al. A multi-institutional study of radiofrequency volumetric tissue reduction for OSAS. *Otolaryngol Head Neck Surg* 2001;125(4):303–11.

146. Tomes CS. The bearing of the development of the jaws on irregularities. *Dental Cosmos* 1873;115:292–6.
147. Carpenter JE. Mental aberration and attending hypertrophic rhinitis with subacute otitis media. *JAMA* 1892;19:539–42.
148. Cline CL. The effects of intra-nasal obstruction on the general health. *Med Surg Rep* 1892;67:259–60.
149. Hill W. On some causes of backwardness and stupidity of children. *BMJ* 1889;2: 711–2.
150. Wells WA. Some nervous and mental manifestations occurring in connection with nasal disease. *Am J Med Sci* 1898;116:677–92.
151. Koutsourelakis I, Georgouloupoulos G, Perraki E, et al. Randomised trial of nasal surgery for fixed nasal obstruction in obstructive sleep apnoea. *Eur Respir J* 2008;31(1):110–7.
152. Pirsig W, Verse T. Long-term results in the treatment of obstructive sleep apnea. *Eur Arch Otorhinolaryngol* 2000;257(10):570–7.
153. Powell NB, Zonato AI, Weaver EM, et al. Radiofrequency treatment of turbinate hypertrophy in subjects using continuous positive airway pressure: a randomized, double-blind, placebo-controlled clinical pilot trial. *Laryngoscope* 2001; 111(10):1783–90.
154. Friedman M, Tanyeri H, Lim JW, et al. Effect of improved nasal breathing on obstructive sleep apnea. *Otolaryngol Head Neck Surg* 2000;122(1):71–4.
155. Olsen KD, Kern EB. Nasal influences on snoring and obstructive sleep apnea. *Mayo Clin Proc* 1990;65(8):1095–105.
156. Li HY, Lin Y, Chen NH, et al. Improvement in quality of life after nasal surgery alone for patients with obstructive sleep apnea and nasal obstruction. *Arch Otolaryngol Head Neck Surg* 2008;134(4):429–33.
157. Li KK, Powell NB, Riley RW, et al. Radiofrequency volumetric tissue reduction for treatment of turbinate hypertrophy: a pilot study. *Otolaryngol Head Neck Surg* 1998;119(6):569–73.
158. Kezirian EJ, Powell NB, Riley RW, et al. Incidence of complications in radiofrequency treatment of the upper airway. *Laryngoscope* 2005;115(7):1298–304.
159. Li KK, Powell NB, Riley RW, et al. Radiofrequency volumetric reduction of the palate: an extended follow-up study. *Otolaryngol Head Neck Surg* 2000; 122(3):410–4.
160. Coleman SC, Smith TL. Midline radiofrequency tissue reduction of the palate for bothersome snoring and sleep-disordered breathing: a clinical trial. *Otolaryngol Head Neck Surg* 2000;122(3):387–94.
161. Powell NB, Riley RW, Troell RJ, et al. Radiofrequency volumetric tissue reduction of the palate in subjects with sleep-disordered breathing. *Chest* 1998;113(5): 1163–74.
162. Stuck BA, Sauter A, Hormann K, et al. Radiofrequency surgery of the soft palate in the treatment of snoring. A placebo-controlled trial. *Sleep* 2005;28(7):847–50.
163. Hofmann T, Schwantzer G, Reckenzaun E, et al. Radiofrequency tissue volume reduction of the soft palate and UPPP in the treatment of snoring. *Eur Arch Otorhinolaryngol* 2006;263(2):164–70.
164. Blumen MB, Dahan S, Fleury B, et al. Radiofrequency ablation for the treatment of mild to moderate obstructive sleep apnea. *Laryngoscope* 2002;112(11): 2086–92.
165. Brown DJ, Kerr P, Kryger M. Radiofrequency tissue reduction of the palate in patients with moderate sleep-disordered breathing. *J Otolaryngol* 2001;30(4): 193–8.

166. Back LJ, Liukko T, Rantanen I, et al. Radiofrequency surgery of the soft palate in the treatment of mild obstructive sleep apnea is not effective as a single-stage procedure: a randomized single-blinded placebo-controlled trial. *Laryngoscope* 2009;119(8):1621–7.
167. Bluestone CD. Current indications for tonsillectomy and adenoidectomy. *Ann Otol Rhinol Laryngol Suppl* 1992;155:58–64.
168. Rosenfeld RM, Green RP. Tonsillectomy and adenoidectomy: changing trends. *Ann Otol Rhinol Laryngol* 1990;99(3 Pt 1):187–91.
169. Waters KA, Cheng AT. Adenotonsillectomy in the context of obstructive sleep apnoea. *Paediatr Respir Rev* 2009;10(1):25–31.
170. Krishna P, LaPage MJ, Hughes LF, et al. Current practice patterns in tonsillectomy and perioperative care. *Int J Pediatr Otorhinolaryngol* 2004;68(6):779–84.
171. Celenk F, Bayazit YA, Yilmaz M, et al. Tonsillar regrowth following partial tonsillectomy with radiofrequency. *Int J Pediatr Otorhinolaryngol* 2008;72(1):19–22.
172. Vlastos IM, Parpounas K, Economides J, et al. Tonsillectomy versus tonsillotomy performed with scissors in children with tonsillar hypertrophy. *Int J Pediatr Otorhinolaryngol* 2008;72(6):857–63.
173. Koltai PJ, Solares CA, Mascha EJ, et al. Intracapsular partial tonsillectomy for tonsillar hypertrophy in children. *Laryngoscope* 2002;112(8 Pt 2 Suppl 100):17–9.
174. Densert O, Desai H, Eliasson A, et al. Tonsillotomy in children with tonsillar hypertrophy. *Acta Otolaryngol* 2001;121(7):854–8.
175. Hultcrantz E, Linder A, Markstrom A. Tonsillectomy or tonsillotomy?—A randomized study comparing postoperative pain and long-term effects. *Int J Pediatr Otorhinolaryngol* 1999;51(3):171–6.
176. Eviatar E, Kessler A, Shlamkovitch N, et al. Tonsillectomy vs. partial tonsillectomy for OSAS in children—10 years post-surgery follow-up. *Int J Pediatr Otorhinolaryngol* 2009;73(5):637–40.
177. Brietzke SE, Gallagher D. The effectiveness of tonsillectomy and adenoidectomy in the treatment of pediatric obstructive sleep apnea/hypopnea syndrome: a meta-analysis. *Otolaryngol Head Neck Surg* 2006;134(6):979–84.
178. Friedman M, Wilson M, Lin HC, et al. Updated systematic review of tonsillectomy and adenoidectomy for treatment of pediatric obstructive sleep apnea/hypopnea syndrome. *Otolaryngol Head Neck Surg* 2009;140(6):800–8.
179. Mitchell RB, Kelly J. Outcome of adenotonsillectomy for obstructive sleep apnea in obese and normal-weight children. *Otolaryngol Head Neck Surg* 2007;137(1):43–8.
180. O'Brien LM, Sitha S, Baur LA, et al. Obesity increases the risk for persisting obstructive sleep apnea after treatment in children. *Int J Pediatr Otorhinolaryngol* 2006;70(9):1555–60.
181. Guilleminault C, Quo S, Huynh NT, et al. Orthodontic expansion treatment and adenotonsillectomy in the treatment of obstructive sleep apnea in prepubertal children. *Sleep* 2008;31(7):953–7.
182. Ye J, Liu H, Zhang G, et al. Postoperative respiratory complications of adenotonsillectomy for obstructive sleep apnea syndrome in older children: prevalence, risk factors, and impact on clinical outcome. *J Otolaryngol Head Neck Surg* 2009;38(1):49–58.
183. Lima Junior JM, Silva VC, Freitas MR. Long term results in the life quality of children with obstructive sleep disorders submitted to adenoidectomy/adenotonsillectomy. *Braz J Otorhinolaryngol* 2008;74(5):718–24.

184. Goldstein NA, Fatima M, Campbell TF, et al. Child behavior and quality of life before and after tonsillectomy and adenoidectomy. *Arch Otolaryngol Head Neck Surg* 2002;128(7):770–5.
185. Mitchell RB, Kelly J. Behavioral changes in children with mild sleep-disordered breathing or obstructive sleep apnea after adenotonsillectomy. *Laryngoscope* 2007;117(9):1685–8.
186. Mitchell RB. Adenotonsillectomy for obstructive sleep apnea in children: outcome evaluated by pre- and postoperative polysomnography. *Laryngoscope* 2007;117(10):1844–54.
187. Rosen GM, Muckle RP, Mahowald MW, et al. Postoperative respiratory compromise in children with obstructive sleep apnea syndrome: can it be anticipated? *Pediatrics* 1994;93(5):784–8.
188. Richter GT, Bower CM. Cervical complications following routine tonsillectomy and adenoidectomy. *Curr Opin Otolaryngol Head Neck Surg* 2006;14(6):375–80.
189. McColley SA, April MM, Carroll JL, et al. Respiratory compromise after adenotonsillectomy in children with obstructive sleep apnea. *Arch Otolaryngol Head Neck Surg* 1992;118(9):940–3.
190. Schroeder JW Jr, Anstead AS, Wong H. Complications in children who electively remain intubated after adenotonsillectomy for severe obstructive sleep apnea. *Int J Pediatr Otorhinolaryngol* 2009;73(8):1095–9.
191. Brigger MT, Brietzke SE. Outpatient tonsillectomy in children: a systematic review. *Otolaryngol Head Neck Surg* 2006;135(1):1–7.
192. Conway W, Fujita S, Zorick F, et al. Uvulopalatopharyngoplasty. One-year follow-up. *Chest* 1985;88(3):385–7.
193. Fujita S, Conway WA, Zorick FJ, et al. Evaluation of the effectiveness of uvulopalatopharyngoplasty. *Laryngoscope* 1985;95(1):70–4.
194. Simmons FB, Guilleminault C, Silvestri R. Snoring, and some obstructive sleep apnea, can be cured by oropharyngeal surgery. *Arch Otolaryngol Head Neck Surg* 1983;109(8):503–7.
195. Fairbanks DN. Uvulopalatopharyngoplasty complications and avoidance strategies. *Otolaryngol Head Neck Surg* 1990;102(3):239–45.
196. Dickson RI, Blokmanis A. Treatment of obstructive sleep apnea by uvulopalatopharyngoplasty. *Laryngoscope* 1987;97(9):1054–9.
197. Friedman M, Landsberg R, Tanyeri H. Submucosal uvulopalatopharyngoplasty. *Op Tec Otolaryngol Head Neck Surg* 2000;11:26–9.
198. Powell N, Riley R, Guilleminault C, et al. A reversible uvulopalatal flap for snoring and sleep apnea syndrome. *Sleep* 1996;19(7):593–9.
199. Li HY, Li KK, Chen NH, et al. Three-dimensional computed tomography and polysomnography findings after extended uvulopalatal flap surgery for obstructive sleep apnea. *Am J Otolaryngol* 2005;26(1):7–11.
200. Li HY, Chen NH, Shu YH, et al. Changes in quality of life and respiratory disturbance after extended uvulopalatal flap surgery in patients with obstructive sleep apnea. *Arch Otolaryngol Head Neck Surg* 2004;130(2):195–200.
201. Li HY, Li KK, Chen NH, et al. Modified uvulopalatopharyngoplasty: the extended uvulopalatal flap. *Am J Otolaryngol* 2003;24(5):311–6.
202. Woodson BT, Toohill RJ. Transpalatal advancement pharyngoplasty for obstructive sleep apnea. *Laryngoscope* 1993;103(3):269–76.
203. Shine NP, Lewis RH. Transpalatal advancement pharyngoplasty for obstructive sleep apnea syndrome: results and analysis of failures. *Arch Otolaryngol Head Neck Surg* 2009;135(5):434–8.

204. Sundaram S, Lim J, Lasserson TJ. Surgery for obstructive sleep apnoea. *Cochrane Database Syst Rev* 2005;(4):CD001004.
205. Conaway JR, Scherr SC, Conaway JR, et al. Multidisciplinary management of the airway in a trauma-induced brain injury patient. *Sleep Breath* 2004;8(3):165–70.
206. Megwalu UC, Piccirillo JF. Methodological and statistical problems in uvulopalatopharyngoplasty research: a follow-up study. *Arch Otolaryngol Head Neck Surg* 2008;134(8):805–9.
207. Lojander J, Maasilta P, Partinen M, et al. Nasal-CPAP, surgery, and conservative management for treatment of obstructive sleep apnea syndrome. A randomized study. *Chest* 1996;110(1):114–9.
208. Khan A, Ramar K, Maddirala S, et al. Uvulopalatopharyngoplasty in the management of obstructive sleep apnea: the Mayo Clinic experience. *Mayo Clin Proc* 2009;84(9):795–800.
209. Sher AE. Upper airway surgery for obstructive sleep apnea. *Sleep Med Rev* 2002;6(3):195–212.
210. Weaver EM, Maynard C, Yueh B. Survival of veterans with sleep apnea: continuous positive airway pressure versus surgery. *Otolaryngol Head Neck Surg* 2004;130(6):659–65.
211. Marti S, Sampol G, Munoz X, et al. Mortality in severe sleep apnoea/hypopnoea syndrome patients: impact of treatment. *Eur Respir J* 2002;20(6):1511–8.
212. Keenan SP, Burt H, Ryan CF, et al. Long-term survival of patients with obstructive sleep apnea treated by uvulopalatopharyngoplasty or nasal CPAP. *Chest* 1994;105(1):155–9.
213. Boot H, Poubion RM, Van Wegen R, et al. Uvulopalatopharyngoplasty for the obstructive sleep apnoea syndrome: value of polysomnography, Mueller manoeuvre and cephalometry in predicting surgical outcome. *Clin Otolaryngol* 1997;22(6):504–10.
214. Katsantonis GP, Maas CS, Walsh JK. The predictive efficacy of the Muller maneuver in uvulopalatopharyngoplasty. *Laryngoscope* 1989;99(7 Pt 1):677–80.
215. Gereau SA, Sher AE, Glovinsky P, et al. Results of uvulopalatopharyngoplasty (UPPP) in patients selected by Mueller Maneuver [abstract]. *Sleep Res* 1986;15(124).
216. Sher AE, Thorpy MJ, Shprintzen RJ, et al. Predictive value of Muller maneuver in selection of patients for uvulopalatopharyngoplasty. *Laryngoscope* 1985;95(12):1483–7.
217. Chandrashekariah R, Shaman Z, Auckley D. Impact of upper airway surgery on CPAP compliance in difficult-to-manage obstructive sleep apnea. *Arch Otolaryngol Head Neck Surg* 2008;134(9):926–30.
218. Han F, Song W, Li J, et al. Influence of UPPP surgery on tolerance to subsequent continuous positive airway pressure in patients with OSAHS. *Sleep Breath* 2006;10(1):37–42.
219. Mortimore IL, Bradley PA, Murray JA, et al. Uvulopalatopharyngoplasty may compromise nasal CPAP therapy in sleep apnea syndrome. *Am J Respir Crit Care Med* 1996;154(6 Pt 1):1759–62.
220. Friedman M, Soans R, Joseph N, et al. The effect of multilevel upper airway surgery on continuous positive airway pressure therapy in obstructive sleep apnea/hypopnea syndrome. *Laryngoscope* 2009;119(1):193–6.
221. Miljeteig H, Mateika S, Haight JS, et al. Subjective and objective assessment of uvulopalatopharyngoplasty for treatment of snoring and obstructive sleep apnea. *Am J Respir Crit Care Med* 1994;150(5 Pt 1):1286–90.

222. Macnab T, Blokmanis A, Dickson RI. Long-term results of uvulopalatopharyngoplasty for snoring. *J Otolaryngol* 1992;21(5):350–4.
223. Jaghagen EL, Berggren D, Dahlqvist A, et al. Prediction and risk of dysphagia after uvulopalatopharyngoplasty and uvulopalatoplasty. *Acta Otolaryngol* 2004; 124(10):1197–203.
224. Lysdahl M, Haraldsson PO. Uvulopalatopharyngoplasty versus laser uvulopalatoplasty: prospective long-term follow-up of self-reported symptoms. *Acta Otolaryngol* 2002;122(7):752–7.
225. Grontved AM, Karup P. Complaints and satisfaction after uvulopalatopharyngoplasty. *Acta Otolaryngol Suppl* 2000;543:190–2.
226. Levring-Jaghagen E, Nilsson ME, Isberg A. Persisting dysphagia after uvulopalatoplasty performed with steel scalpel. *Laryngoscope* 1999;109(1):86–90.
227. Kosztyla-Hojna B, Rogowski M, Olszewska E, et al. [Voice quality evaluation in patients with obstructive sleep apnea syndrome treated with uvulopalatopharyngoplasty (UPPP)]. *Pol Merkur Lekarski* 2008;25(145):46–50 [in Polish].
228. Robinson S, Chia M, Carney AS, et al. Upper airway reconstructive surgery long-term quality-of-life outcomes compared with CPAP for adult obstructive sleep apnea. *Otolaryngol Head Neck Surg* Aug 2009;141(2):257–63.
229. Riley R, Guilleminault C, Powell N, et al. Mandibular osteotomy and hyoid bone advancement for obstructive sleep apnea: a case report. *Sleep* 1984;7(1):79–82.
230. Riley RW, Powell NB, Guilleminault C. Inferior sagittal osteotomy of the mandible with hyoid myotomy-suspension: a new procedure for obstructive sleep apnea. *Otolaryngol Head Neck Surg* 1986;94(5):589–93.
231. Riley RW, Powell NB, Guilleminault C. Inferior mandibular osteotomy and hyoid myotomy suspension for obstructive sleep apnea: a review of 55 patients. *J Oral Maxillofac Surg* 1989;47(2):159–64.
232. Li KK, Riley RW, Powell NB, et al. Obstructive sleep apnea surgery: genioglossus advancement revisited. *J Oral Maxillofac Surg* 2001;59(10):1181–4.
233. Silverstein K, Costello BJ, Giannakopoulos H, et al. Genioglossus muscle attachments: an anatomic analysis and the implications for genioglossus advancement. *Oral Surg Oral Med Oral Pathol Oral Radiol Endod* 2000; 90(6):686–8.
234. Demian NM, Alford J, Takashima M. An alternative technique for genioglossus muscle advancement in phase I surgery in the treatment of obstructive sleep apnea. *J Oral Maxillofac Surg* 2009;67(10):2315–8.
235. Riley RW, Powell NB, Guilleminault C, et al. Maxillary, mandibular, and hyoid advancement: an alternative to tracheostomy in obstructive sleep apnea syndrome. *Otolaryngol Head Neck Surg* 1986;94(5):584–8.
236. Van de Graaff WB, Gottfried SB, Mitra J, et al. Respiratory function of hyoid muscles and hyoid arch. *J Appl Physiol* 1984;57(1):197–204.
237. Patton TJ, Thawley SE, Waters RC, et al. Expansion hyoidplasty: a potential surgical procedure designed for selected patients with obstructive sleep apnea syndrome. Experimental canine results. *Laryngoscope* 1983;93(11 Pt 1):1387–96.
238. Riley RW, Powell NB, Guilleminault C. Obstructive sleep apnea and the hyoid: a revised surgical procedure. *Otolaryngol Head Neck Surg* 1994;111(6):717–21.
239. Bowden MT, Kezirian EJ, Utley D, et al. Outcomes of hyoid suspension for the treatment of obstructive sleep apnea. *Arch Otolaryngol Head Neck Surg* 2005;131(5):440–5.

240. Baisch A, Maurer JT, Hormann K. The effect of hyoid suspension in a multilevel surgery concept for obstructive sleep apnea. *Otolaryngol Head Neck Surg* 2006;134(5):856–61.
241. Stuck BA, Neff W, Hormann K, et al. Anatomic changes after hyoid suspension for obstructive sleep apnea: an MRI study. *Otolaryngol Head Neck Surg* 2005;133(3):397–402.
242. Verse T, Baisch A, Hormann K. [Multi-level surgery for obstructive sleep apnea. Preliminary objective results]. *Laryngorhinootologie* 2004;83(8):516–22 [in German].
243. Vilaseca I, Morello A, Montserrat JM, et al. Usefulness of uvulopalatopharyngoplasty with genioglossus and hyoid advancement in the treatment of obstructive sleep apnea. *Arch Otolaryngol Head Neck Surg* 2002;128(4):435–40.
244. Neruntarat C. Genioglossus advancement and hyoid myotomy under local anesthesia. *Otolaryngol Head Neck Surg* 2003;129(1):85–91.
245. Neruntarat C. Genioglossus advancement and hyoid myotomy: short-term and long-term results. *J Laryngol Otol* 2003;117(6):482–6.
246. den Herder C, van Tinteren H, de Vries N, et al. Hyoidthyroidpexia: a surgical treatment for sleep apnea syndrome. *Laryngoscope* 2005;115(4):740–5.
247. Li KK, Powell NB, Riley RW, et al. Distraction osteogenesis in adult obstructive sleep apnea surgery: a preliminary report. *J Oral Maxillofac Surg* 2002;60(1):6–10.
248. Morovic CG, Monasterio L. Distraction osteogenesis for obstructive apneas in patients with congenital craniofacial malformations. *Plast Reconstr Surg* 2000;105(7):2324–30.
249. Williams JK, Maull D, Grayson BH, et al. Early decannulation with bilateral mandibular distraction for tracheostomy-dependent patients. *Plast Reconstr Surg* 1999;103(1):48–57.
250. Cohen SR, Ross DA, Burstein FD, et al. Skeletal expansion combined with soft-tissue reduction in the treatment of obstructive sleep apnea in children: physiologic results. *Otolaryngol Head Neck Surg* 1998;119(5):476–85.
251. McCarthy JG, Schreiber J, Karp N, et al. Lengthening the human mandible by gradual distraction. *Plast Reconstr Surg* 1992;89(1):1–8.
252. Spire JP, Kuo PC, Campbell N. Maxillo-facial surgical approach: an introduction and review of mandibular advancement. *Bull Eur Physiopathol Respir* 1983;19(6):604–6.
253. Powell N, Guilleminault C, Riley R, et al. Mandibular advancement and obstructive sleep apnea syndrome. *Bull Eur Physiopathol Respir* 1983;19(6):607–10.
254. Jamieson A, Guilleminault C, Partinen M, et al. Obstructive sleep apneic patients have craniomandibular abnormalities. *Sleep* 1986;9(4):469–77.
255. Bell RB, Turvey TA. Skeletal advancement for the treatment of obstructive sleep apnea in children. *Cleft Palate Craniofac J* 2001;38(2):147–54.
256. Cao M, Li K, Guilleminault C. Maxillomandibular advancement surgery for obstructive sleep apnea treatment. *Minerva Pneumol* 2008;47:203–12.
257. Li KK, Guilleminault C, Riley RW, et al. Obstructive sleep apnea and maxillomandibular advancement: an assessment of airway changes using radiographic and nasopharyngoscopic examinations. *J Oral Maxillofac Surg* 2002;60(5):526–30 [discussion: 531].
258. Wickwire NA, White RP Jr, Proffit WR. The effect of mandibular osteotomy on tongue position. *J Oral Maxillofac Surg* 1972;30(3):184–90.
259. Schendel SA, Oeschlaeger M, Wolford LM, et al. Velopharyngeal anatomy and maxillary advancement. *J Maxillofac Surg* 1979;7(2):116–24.

260. Froberg U, Greco JM. [Maxillary osteotomy: an alternative treatment concept for obstructive sleep apnea syndrome]. *Dtsch Z Mund Kiefer Gesichtschir* 1990;14(5):343–7 [in German].
261. Greco JM, Froberg U, Van Sickels JE. Cephalometric analysis of long-term airway space changes with maxillary osteotomies. *Oral Surg Oral Med Oral Pathol* 1990;70(5):552–4.
262. Walker DA, Turvey TA, Warren DW. Alterations in nasal respiration and nasal airway size following superior repositioning of the maxilla. *J Oral Maxillofac Surg* 1988;46(4):276–81.
263. Guenther TA, Sather AH, Kern EB. The effect of Le Fort I maxillary impaction on nasal airway resistance. *Am J Orthod Dentofacial Orthop* Apr 1984;85(4):308–15.
264. Yu CC, Hsiao HD, Lee LC, et al. Computational fluid dynamic study on obstructive sleep apnea syndrome treated with maxillomandibular advancement. *J Craniofac Surg* 2009;20(2):426–30.
265. Waite PD, Shettar SM. Maxillomandibular advancement surgery: a cure for obstructive sleep apnea syndrome. *Oral Maxillofac Surg Clin North Am* 1995;7(2):327–36.
266. Holtz JE, Guilleminault C. Maxillomandibular advancement for the treatment of obstructive sleep apnea: a systematic review and meta-analysis. *Sleep Med Rev* 2010. [Epub ahead of print].
267. Li K, Powell N, Riley R, et al. Long-term results of maxillomandibular advancement surgery. *Sleep Breath* 2000;4(3):137–9.
268. Conradt R, Hochban W, Brandenburg U, et al. Long-term follow-up after surgical treatment of obstructive sleep apnoea by maxillomandibular advancement. *Eur Respir J* 1997;10(1):123–8.
269. Lye KW, Waite PD, Meara D, et al. Quality of life evaluation of maxillomandibular advancement surgery for treatment of obstructive sleep apnea. *J Oral Maxillofac Surg* 2008;66(5):968–72.
270. Dekeister C, Lacassagne L, Tiberge M, et al. [Mandibular advancement surgery in patients with severe obstructive sleep apnea uncontrolled by continuous positive airway pressure. A retrospective review of 25 patients between 1998 and 2004]. *Rev Mal Respir* 2006;23(5 Pt 1):430–7 [in French].
271. Hoekema A, de Lange J, Stegenga B, et al. Oral appliances and maxillomandibular advancement surgery: an alternative treatment protocol for the obstructive sleep apnea-hypopnea syndrome. *J Oral Maxillofac Surg* 2006;64(6):886–91.
272. Smatt Y, Ferri J. Retrospective study of 18 patients treated by maxillomandibular advancement with adjunctive procedures for obstructive sleep apnea syndrome. *J Craniofac Surg* 2005;16(5):770–7.
273. Goh YH, Lim KA. Modified maxillomandibular advancement for the treatment of obstructive sleep apnea: a preliminary report. *Laryngoscope* 2003;113(9):1577–82.
274. Wagner I, Coiffier T, Sequent C, et al. [Surgical treatment of severe sleep apnea syndrome by maxillomandibular advancing or mental transposition]. *Ann Otolaryngol Chir Cervicofac* 2000;117(3):137–46 [in French].
275. Prinsell JR. Maxillomandibular advancement surgery in a site-specific treatment approach for obstructive sleep apnea in 50 consecutive patients. *Chest* 1999;116(6):1519–29.
276. Guilleminault C, Quera-Salva MA, Powell NB, et al. Maxillo-mandibular surgery for obstructive sleep apnoea. *Eur Respir J* 1989;2(7):604–12.

277. Conradt R, Hochban W, Heitmann J, et al. Sleep fragmentation and daytime vigilance in patients with OSA treated by surgical maxillomandibular advancement compared to CPAP therapy. *J Sleep Res* 1998;7(3):217–23.
278. Conradt R, Hochban W, Brandenburg U, et al. [nCPAP therapy and maxillary and mandibular osteotomy compared: attention during the day in obstructive sleep apnea]. *Wien Med Wochenschr* 1996;146(13–14):372–4 [in German].
279. Hochban W, Brandenburg U, Peter JH. Surgical treatment of obstructive sleep apnea by maxillomandibular advancement. *Sleep* 1994;17(7):624–9.
280. Hendler BH, Costello BJ, Silverstein K, et al. A protocol for uvulopalatopharyngoplasty, mortised genioplasty, and maxillomandibular advancement in patients with obstructive sleep apnea: an analysis of 40 cases. *J Oral Maxillofac Surg* 2001;59(8):892–7.
281. Nimkarn Y, Miles PG, Waite PD. Maxillomandibular advancement surgery in obstructive sleep apnea syndrome patients: long-term surgical stability. *J Oral Maxillofac Surg* 1995;53(12):1414–8.
282. Riley RW, Powell NB, Guilleminault C. Maxillofacial surgery and nasal CPAP. A comparison of treatment for obstructive sleep apnea syndrome. *Chest* 1990; 98(6):1421–5.
283. Miles PG, Nimkarn Y. Maxillomandibular advancement surgery in patients with obstructive sleep apnea: mandibular morphology and stability. *Int J Adult Orthodon Orthognath Surg* 1995;10(3):193–200.
284. Louis PJ, Waite PD, Austin RB. Long-term skeletal stability after rigid fixation of Le Fort I osteotomies with advancements. *Int J Oral Maxillofac Surg* 1993;22(2): 82–6.
285. Waite PD, Wooten V. Maxillomandibular advancement: a surgical treatment of obstructive sleep apnea. In: Bell WH, editor, *Modern practice in orthognathic and reconstructive surgery*, vol. 3. Philadelphia: WB Saunders; 1992. p. 2042–59.
286. Lu XF, Zhu M, He JD, et al. [Uvulopalatopharyngoplasty and maxillomandibular advancement for obese patients with obstructive sleep apnea hypopnea syndrome: a preliminary report]. *Zhonghua Kou Qiang Yi Xue Za Zhi* 2007; 42(4):199–202 [in Chinese].
287. Li KK, Riley RW, Powell NB, et al. Obstructive sleep apnea surgery: patient perspective and polysomnographic results. *Otolaryngol Head Neck Surg* 2000;123(5):572–5.
288. Bettega G, Pepin JL, Veale D, et al. Obstructive sleep apnea syndrome. Fifty-one consecutive patients treated by maxillofacial surgery. *Am J Respir Crit Care Med* 2000;162(2 Pt 1):641–9.
289. Li KK, Riley RW, Powell NB, et al. Patient's perception of the facial appearance after maxillomandibular advancement for obstructive sleep apnea syndrome. *J Oral Maxillofac Surg* 2001;59(4):377–80 [discussion: 380–1].
290. Li KK, Riley RW, Powell NB, et al. Maxillomandibular advancement for persistent obstructive sleep apnea after phase I surgery in patients without maxillomandibular deficiency. *Laryngoscope* 2000;110(10 Pt 1):1684–8.
291. Matsuo A, Nakai T, Toyoda J, et al. Good esthetic results after modified maxillo-mandibular advancement for obstructive sleep apnea syndrome. *Sleep Biol Rhythms* 2009;7:3–10.
292. Conley RS, Legan HL. Correction of severe obstructive sleep apnea with bimaxillary transverse distraction osteogenesis and maxillomandibular advancement. *Am J Orthod Dentofacial Orthop* 2006;129(2):283–92.

293. Guilleminault C, Li KK. Maxillomandibular expansion for the treatment of sleep-disordered breathing: preliminary result. *Laryngoscope* 2004;114(5):893–6.
294. Friedman M, Vidyasagar R, Bliznikas D, et al. Patient selection and efficacy of pillar implant technique for treatment of snoring and obstructive sleep apnea/hypopnea syndrome. *Otolaryngol Head Neck Surg* 2006;134(2):187–96.
295. Friedman M, Schalch P, Lin HC, et al. Palatal implants for the treatment of snoring and obstructive sleep apnea/hypopnea syndrome. *Otolaryngol Head Neck Surg* 2008;138(2):209–16.
296. Nordgard S, Stene BK, Skjostad KW. Soft palate implants for the treatment of mild to moderate obstructive sleep apnea. *Otolaryngol Head Neck Surg* 2006;134(4):565–70.
297. Nordgard S, Stene BK, Skjostad KW, et al. Palatal implants for the treatment of snoring: long-term results. *Otolaryngol Head Neck Surg* 2006;134(4):558–64.
298. Maurer JT, Hein G, Verse T, et al. Long-term results of palatal implants for primary snoring. *Otolaryngol Head Neck Surg* 2005;133(4):573–8.
299. Angell EH. Treatment of irregularity of the permanent or adult teeth. *Dental Cosmos* 1860;1:540–4 [discussion: 599–600].
300. Lagravere MO, Heo G, Major PW, et al. Meta-analysis of immediate changes with rapid maxillary expansion treatment [comment]. *J Am Dent Assoc* 2006;137(1):44–53.
301. Monini S, Malagola C, Villa MP, et al. Rapid maxillary expansion for the treatment of nasal obstruction in children younger than 12 years. *Arch Otolaryngol Head Neck Surg* 2009;135(1):22–7.
302. Basciftci FA, Mutlu N, Karaman AI, et al. Does the timing and method of rapid maxillary expansion have an effect on the changes in nasal dimensions? *Angle Orthod* 2002;72(2):118–23.
303. Gray LP. Results of 310 cases of rapid maxillary expansion selected for medical reasons. *J Laryngol Otol* 1975;89(6):601–14.
304. Timms DJ. Rapid maxillary expansion. Chicago: Quintessence Publishing; 1981.
305. Eysell. Über die Verengung der Nasenhöhle, bedingt durch Gaumenenge und Anomole Zahnstellung [Narrow oropharynx and abnormal dental position due to narrow nasal passages]. *Dtsche Monat Zhk* 1886;12:481 [in German].
306. White BC, Woodside DG, Cole P. The effect of rapid maxillary expansion on nasal airway resistance. *J Otolaryngol* 1989;18(4):137–43.
307. Timms DJ. Rapid maxillary expansion in the treatment of nasal obstruction and respiratory disease. *Ear Nose Throat J* 1987;66(6):242–7.
308. Warren DW, Hershey HG, Turvey TA, et al. The nasal airway following maxillary expansion. *Am J Orthod Dentofacial Orthop* 1987;91(2):111–6.
309. Timms DJ. The effect of rapid maxillary expansion on nasal airway resistance. *Br J Orthod* 1986;13(4):221–8.
310. Hershey HG, Stewart BL, Warren DW. Changes in nasal airway resistance associated with rapid maxillary expansion. *Am J Orthod* 1976;69(3):274–84.
311. Wertz RA. Changes in nasal airflow incident to rapid maxillary expansion. *Angle Orthod* 1968;38(1):1–11.
312. Linder-Aronson S, Aschan G. Nasal resistance to breathing and palatal height before and after expansion of the median palatine suture. *Odontol Revy* 1963;14:254–70.
313. Woods M, Wiesenfeld D, Probert T. Surgically-assisted maxillary expansion. *Aust Dent J* 1997;42(1):38–42.
314. de Moura CP, Andrade D, Cunha LM, et al. Down syndrome: otolaryngological effects of rapid maxillary expansion. *J Laryngol Otol* 2008;122(12):1318–24.

315. Timms DJ. The reduction of nasal airway resistance by rapid maxillary expansion and its effect on respiratory disease. *J Laryngol Otol* 1984; 98(4):357–62.
316. Palmisano RG, Wilcox I, Sullivan CE, et al. Treatment of snoring and obstructive sleep apnoea by rapid maxillary expansion. *Aust N Z J Med* 1996;26(3):428–9.
317. Villa MP, Malagola C, Pagani J, et al. Rapid maxillary expansion in children with obstructive sleep apnea syndrome: 12-month follow-up. *Sleep Med* 2007;8(2): 128–34.
318. Pirelli P, Saponara M, Attanasio G, et al. Obstructive sleep apnoea syndrome (OSAS) and rhino-tuberic dysfunction in children: therapeutic effects of RME therapy. *Prog Orthod* 2005;6(1):48–61.
319. Pirelli P, Saponara M, Guilleminault C. Rapid maxillary expansion in children with obstructive sleep apnea syndrome. *Sleep* 2004;27(4):761–6.
320. Holty JEC, Guilleminault C. Maxillo-mandibular expansion and advancement for the treatment of sleep-disordered breathing in children and adults. *Semin Orthod*, in press.
321. Cistulli PA, Palmisano RG, Poole MD. Treatment of obstructive sleep apnea syndrome by rapid maxillary expansion. *Sleep* 1998;21(8):831–5.
322. Friedman M, Lin HC, Gurpinar B, et al. Minimally invasive single-stage multilevel treatment for obstructive sleep apnea/hypopnea syndrome. *Laryngoscope* 2007;117(10):1859–63.
323. Verse T, Baisch A, Maurer JT, et al. Multilevel surgery for obstructive sleep apnea: short-term results. *Otolaryngol Head Neck Surg* 2006;134(4):571–7.
324. Li HY, Wang PC, Hsu CY, et al. Same-stage palatopharyngeal and hypopharyngeal surgery for severe obstructive sleep apnea. *Acta Otolaryngol* 2004; 124(7):820–6.
325. Riley RW, Powell NB, Guilleminault C. Obstructive sleep apnea syndrome: a review of 306 consecutively treated surgical patients. *Otolaryngol Head Neck Surg* 1993;108(2):117–25.
326. Li KK, Powell NB, Riley RW, et al. Overview of phase I surgery for obstructive sleep apnea syndrome. *Ear Nose Throat J* 1999;78(11):836–7.
327. Li KK, Riley RW, Powell NB, et al. Overview of phase II surgery for obstructive sleep apnea syndrome. *Ear Nose Throat J* 1999;78(11):851.
328. Flegal KM, Carrol MD, Ogden CL, et al. Prevalence and trends in obesity among US adults, 1999–2000. *JAMA* 2002;288:1723–7.
329. Brolin RE. Gastric bypass. *Surg Clin North Am* 1967;81(5):1077–95.
330. Santry HP, Gillen DL, Lauderdale DS. Trends in bariatric surgical procedures. *JAMA* 2005;294(15):1909–17.
331. Flum DR, Belle SH, King WC, et al. Perioperative safety in the longitudinal assessment of bariatric surgery. *N Engl J Med* 2009;361(5):445–54.
332. Sjostrom L, Narbro K, Sjostrom CD, et al. Effects of bariatric surgery on mortality in Swedish obese subjects. *N Engl J Med* 2007;357(8):741–52.
333. Buchwald H, Avidor Y, Braunwald E, et al. Bariatric surgery: a systematic review and meta-analysis. *JAMA* 2004;292(14):1724–37.
334. Gastrointestinal surgery for severe obesity: National Institutes of Health Consensus Development Conference Statement. *Am J Clin Nutr* 1992;55: 615S–9S.
335. Anonymous. Gastrointestinal surgery for severe obesity. NIH Consensus Statement Online 1991;9(1):1–20.
336. Peppard PE, Young T, Palta M, et al. Longitudinal study of moderate weight change and sleep-disordered breathing. *JAMA* 2000;284(23):3015–21.

337. Smith PL, Gold AR, Meyers DA, et al. Weight loss in mildly to moderately obese patients with obstructive sleep apnea. *Ann Intern Med* 1985;103(6 (Pt 1)):850–5.
338. Greenburg DL, Lettieri CJ, Eliasson AH. Effects of surgical weight loss on measures of obstructive sleep apnea: a meta-analysis. *Am J Med* 2009; 122(6):535–42.
339. Holty JE, Levesque BG, Schneider-Chafen J, et al. Obstructive sleep apnea is prevalent and persistent among patients undergoing bariatric surgery: a systematic review [abstract presentation]. *Dig Dis Sci* 2010.